



Raimondi, F., Shihab, N., Gutierrez-Quintana, R., Smith, A., Trevail, R., Sanchez-Masian, D., & Smith, P. (2017). Magnetic resonance imaging findings in epileptic cats with a normal interictal neurological examination: 188 cases. *Veterinary Record*.
<https://doi.org/10.1136/vr.104142>

Peer reviewed version

Link to published version (if available):
[10.1136/vr.104142](https://doi.org/10.1136/vr.104142)

[Link to publication record on the Bristol Research Portal](#)
PDF-document

This is the author accepted manuscript (AAM). The final published version (version of record) is available online via British Veterinary Association at <http://veterinaryrecord.bmj.com/content/early/2017/04/06/vr.104142> . Please refer to any applicable terms of use of the publisher.

University of Bristol – Bristol Research Portal

General rights

This document is made available in accordance with publisher policies. Please cite only the published version using the reference above. Full terms of use are available:
<http://www.bristol.ac.uk/red/research-policy/pure/user-guides/brp-terms/>

Magnetic Resonance Imaging findings in epileptic cats with a normal interictal neurological examination: 188 cases

Journal:	<i>Veterinary Record</i>
Manuscript ID	vetrec-2016-104142.R2
Article Type:	Paper
Date Submitted by the Author:	06-Mar-2017
Complete List of Authors:	Raimondi, Francesca; Southern Counties Veterinary Specialists LLP, Neurology Shihab, Nadia; Southern Counties Veterinary Specialists, Nadia is an ECVN Diplomate Gutierrez-Quintana, Rodrigo; University of Glasgow, School of Veterinary Medicine Smith, Alexander; Langford Veterinary Services, small animal hospital Trevail, Raquel; Southern Counties Veterinary Specialists LLP, Neurology Sanchez-Masian, Daniel; Small Animal Teaching Hospital, University of Liverpool, Neurology/Neurosurgery Smith, Pete; Davies Veterinary Specialists,
Abstract:	<p>Epilepsy is a common neurological condition in dogs and cats. Although an increased likelihood of significant brain lesions with age has been identified in neurologically normal dogs with epileptic seizures, the underlying aetiology of epileptic seizures in cats that present with normal physical and neurological examinations remains unknown. In this cross – sectional study, we examined magnetic resonance imaging (MRI) findings in a large population of cats with a normal interictal physical and neurological examination. We hypothesised that age would have an impact on the prevalence of detectable lesions.</p> <p>First, following the guidelines for dogs and in accordance with previous studies, we divided the cats into three age groups (aged 1 year or younger, between 1 and 6 and older than 6) and calculated the proportion of cats with a detectable lesion on MRI in these groups. In the first group, 3/32 cats (9.4%) had significant MRI abnormalities that were all consistent with congenital malformation; in the second group, only 5/92 (5.4%) MRI scans were abnormal and in the third group, 15/ 65 (23.1%) cats showed abnormal findings that were predominantly lesions of neoplastic origin.</p> <p>Second, to investigate the impact of age further, data were investigated as a continuous variable using receiver operating characteristic (ROC) analysis. This indicated an optimal cut off age of 5 years, above which MRI abnormalities were more likely, with an increase in the odds of a significant structural lesion increasing by 14% per year.</p>

1
2
3
4
5
6
7
8
9
10
11
12
13
14
15
16
17
18
19
20
21
22
23
24
25
26
27
28
29
30
31
32
33
34
35
36
37
38
39
40
41
42
43
44
45
46
47
48
49
50
51
52
53
54
55
56
57
58
59
60

SCHOLARONE™
Manuscripts

Confidential: For Review Only

1 Magnetic resonance imaging findings in epileptic cats with a normal interictal
2 neurological examination: 188 cases

3 Authors:

4 Corresponding author:

5 Francesca Raimondi, DVM MRCVS

6 Southern Counties Veterinary Specialists (SCVS)

7 6 Forest Corner Farm

8 Ringwood, Hampshire, BH24 3JW, UK

9 francy.raimondi@gmail.com

10 tel. +44 1425 485615

11 fax. +44 1425 480849

12
13 Nadia Shihab, MAVetMB Dip ECVN MRCVS

14 Southern Counties Veterinary Specialists (SCVS)

15 6, Forest Corner Farm,

16 Ringwood, Hampshire, BH24 3JW, UK.

17
18 Rodrigo Gutierrez-Quintana, MVZ MVM Dip ECVN MRCVS

19 School of Veterinary Medicine,

20 Bearsden Rd, Bearsden, Glasgow, G61 1QH, UK

21
22 Alexander Smith, BVetMed, MRCVS

23 Langford Small Animal Referral Hospital,

24 Langford Road, Bristol, BS40 5DU, UK

25

1
2
3
4
5
6
7
8
9
10
11
12
13
14
15
16
17
18
19
20
21
22
23
24
25
26
27
28
29
30
31
32
33
34
35
36
37
38
39
40
41
42
43
44
45
46
47
48
49
50
51
52
53
54
55
56
57
58
59
60

26 Raquel Trevail, DVM Dip ECVN MRCVS

27 Southern Counties Veterinary Specialists (SCVS)

28 6 Forest Corner Farm,
29 Ringwood, Hampshire, BH24 3JW, UK.

30

31 Daniel Sanchez-Masian, Lic Vet Dip ECVN MRCVS.

32 Small Animal Teaching Hospital,
33 Chester High Rd, Neston, CH64 7TE, UK

34

35 Peter M. Smith, BSc, BVM&S, PhD, Dip ECVN, MRCVS.

36 Davies Veterinary Specialists
37 Manor Farm Business Park

38 Higham Gobion, Hitchin, SG5 3HR, UK

39

40 Keywords: Feline, epilepsy, brain, magnetic resonance imaging

41

42 Word count: 3925

43

44

45

46

47

48

49

50

51

52

53

54

55

1
2
3 51 Abstract:
4

5 52 Epilepsy is a common neurological condition in dogs and cats. Although an increased
6
7 53 likelihood of significant brain lesions with age has been identified in neurologically normal
8
9
10 54 dogs with epileptic seizures, the underlying aetiology of epileptic seizures in cats that present
11
12 55 with normal physical and neurological examinations remains unknown. In this cross –
13
14 56 sectional study, we examined magnetic resonance imaging (MRI) findings in a large
15
16 57 population of cats with a normal interictal physical and neurological examination. We
17
18 58 hypothesised that age would have an impact on the prevalence of detectable lesions.
19

20
21
22 59 First, following the guidelines for dogs and in accordance with previous studies, we divided
23
24 60 the cats into three age groups (aged 1 year or younger, between 1 and 6 and older than 6) and
25
26 61 calculated the proportion of cats with a detectable lesion on MRI in these groups. In the first
27
28 62 group, 3/32 cats (9.4%) had significant MRI abnormalities that were all consistent with
29
30 63 congenital malformation; in the second group, only 5/92 (5.4%) MRI scans were abnormal
31
32 64 and in the third group, 15/ 65 (23.1%) cats showed abnormal findings that were
33
34 65 predominantly lesions of neoplastic origin.
35
36

37
38 66 Second, to investigate the impact of age further, data were investigated as a continuous
39
40 67 variable using receiver operating characteristic (ROC) analysis. This indicated an optimal cut
41
42 68 off age of 5 years, above which MRI abnormalities were more likely, with an increase in the
43
44 69 odds of a significant structural lesion increasing by 14% per year.
45
46

47 70

48
49 71

50
51 72

52
53 73

54
55 74
56
57
58
59
60

1
2
3 75 Introduction

4
5 76 Epileptic seizures are transient paroxysmal disturbances in brain function caused by an
6
7 77 imbalance in excitatory and inhibitory neuronal transmission. They arise through
8
9
10 78 disturbances in forebrain function and can be caused by metabolic derangements, by genetic
11
12 79 or acquired abnormalities in neuronal function or by structural brain disease (Berendt and
13
14 80 others 2015, Berg and others 2011, Finnerty and others 2014, Munana 2013, Pakodzy and
15
16 81 others 2014, Wahle and others 2014). The diagnostic approach to cats with epileptic seizures
17
18 82 includes complete physical and neurological examinations, analysis of various biochemical
19
20 83 and haematological parameters, advanced imaging of the brain and analyses of cerebrospinal
21
22 84 fluid when appropriate (Bailey and others 2009, De Risio and others 2015, Rusbridge 2005).
23
24 85 Understanding the probability of a significant structural brain lesion in cats with epileptic
25
26 86 seizures helps clinicians assess the need for advanced brain imaging. Although cats with
27
28 87 neurological deficits have a high risk of structural brain disease, a significant lesion in a non-
29
30 88 eloquent region of the brain might be undetectable on neurological examination (Schwartz
31
32 89 and others 2011, Smith and others 2008). As a result, many animals that appear
33
34 90 neurologically normal will have an identifiable lesion on magnetic resonance imaging (MRI).
35
36 91 An increase likelihood of a significant brain lesion with age has been established in
37
38 92 neurologically normal dogs with recurrent seizures, and studies have indicated a substantially
39
40 93 higher risk in dogs older than six years of age, which is primarily related to the higher
41
42 94 prevalence of neoplastic lesions in older animals (Armasu and others 2014, De Risio and
43
44 95 others 2015, Schwartz and others 2013, Smith and others 2008).
45
46 96 Although applying the same patterns to cats may seem reasonable, such an assumption is
47
48 97 questionable. First, idiopathic epilepsy is thought to be relatively rare in cats, which
49
50 98 decreases the likelihood of diagnosing this form of epilepsy and increases the likelihood of
51
52 99 young cats presenting with a significant brain lesion than similarly aged dogs. Second, cats
53
54
55
56
57
58
59
60

1
2
3 100 with meningioma, which is the most common brain neoplasm in cats, are less likely to have
4
5 101 epileptic seizures than dogs with brain neoplasia (Bagley and others 1999; Cameron and
6
7 102 others 2015, Schwartz and others 2011, Snyder and others 2006, Tomek and others 2006,
8
9 103 Troxel and others 2003) which may decrease the prevalence of identifiable lesions in geriatric
10
11 104 cats compared with that in dogs.

12
13
14 105 To investigate the prevalence of structural brain disease in cats of varying ages suffering
15
16 106 from epileptic seizures we examined the MRI findings of a large population of cats with
17
18 107 normal interictal physical and neurological examinations and without significant
19
20 108 abnormalities on haematology or serum biochemistry analysis (including fasting bile acids
21
22 109 and electrolytes).

23
24
25 110 In accordance with the international veterinary epilepsy task force (IVETF) guide lines for
26
27 111 dogs (De Risio and others 2015), we divided the cats into three age groups (aged or younger
28
29 112 than one year, between one and six years and older than 6 years) and we compared the
30
31 113 proportion of cats with a detectable lesion on MRI in these different groups. We also
32
33 114 analysed whether there was an optimal cut off age at which structural epilepsy was more
34
35 115 prevalent than idiopathic epilepsy and we assessed the association of age with the likelihood
36
37 116 of suffering from structural epilepsy.

38
39
40 117 Materials and methods

41
42
43
44 118 Electronic and hardcopy records of five United Kingdom (UK) referral hospitals (Southern
45
46 119 Counties Veterinary Specialists, Hampshire (2009 to 2016); Davies Veterinary Specialists,
47
48 120 Hertfordshire (2007 to 2016); Langford Small Animal Veterinary Referral Hospital, North
49
50 121 Somerset (2009 to 2016), Small Animal Hospital, University of Glasgow (2008 to 2016);
51
52 122 and Small Animal Teaching Hospital, Liverpool, Merseyside (2009 to 2016)) were searched
53
54 123 to identify the records of cats presenting with epileptic seizures that were either focal,
55
56 124 generalized or focal epileptic seizures evolving into generalized seizures.

1
2
3 125 The following information was obtained from the medical record: breed, sex, age of onset of
4
5 126 epileptic seizures, results of neurologic and physical examinations, and clinicopathological
6
7 127 tests performed, diagnostic imaging results and cerebrospinal fluid (CSF) analysis when
8
9 128 performed.

11 129 The definition and classification of the epilepsy and seizure types were based on the IVETF
13
14 130 recommendations (Berendt and others 2015).

16 131 Epilepsy was classified as either structural epilepsy or idiopathic epilepsy of unknown origin.

18 132 Epileptic seizures were classified in three different groups: focal epileptic seizures,
20
21 133 generalized epileptic seizures and focal epileptic seizures evolving into generalized epileptic
22
23 134 seizures (secondary generalization) (Berendt and others 2015).

25 135 Cats were included in the study if they had suffered at least two unprovoked epileptic
26
27 136 seizures in a time frame of at least 24 hours (Berendt and others 2015) but
28
29 137 were excluded if they were known or suspected to have reactive seizures resulting from toxin
30
31 138 exposure, a metabolic syndrome, or an anaesthesia-related incident.

34 139 All cats included in the study were required to have a normal physical and interictal
35
36 140 neurological examination, designated by a recognised specialist in veterinary neurology, and
37
38 141 an MRI scan analysed by a recognised imaging specialist. In cats that presented in status
39
40 142 epilepticus, neurological evaluation was postponed until complete recovery from the seizure
41
42 143 to avoid temporary post-ictal deficits.

45 144 All cats underwent screening tests, including haematology, serum biochemistry analysis,
46
47 145 electrolytes and fasting bile acids and those with significant abnormalities were excluded.

49 146 Additional tests for extracranial disorders were performed when clinically appropriate and
50
51 147 included post prandial bile acid and ammonia concentrations, thoracic radiography,
52
53 148 abdominal ultrasonography, echo- and electrocardiography, serial blood pressure
54
55 149 measurements, thyroxine (T4) concentration and serological tests for certain infectious agents
56
57
58
59
60

1
2
3 150 (feline leukemia virus (FELV), feline immunodeficiency virus (FIV), *Toxoplasma gondii* and
4
5 151 Feline Coronavirus). These were performed at the discretion of the clinician and only cats
6
7 152 with normal findings on these additional tests were included in the study.
8

9
10 153 A CSF analysis at a reference laboratory was required for inclusion in this study unless the
11
12 154 MRI findings indicated increased intracranial pressure and an increased risk of injury to the
13
14 155 patient. All cats included underwent brain MRI under general anaesthesia using one of the
15
16 156 following MR scanners depending on the institution: 0.4 Tesla (T) MRI (Aperto MRI
17
18 157 Hitachi, Wellingborough, UK); 1 T (Panorama Philips, Guildford, UK); 1.5 T (Petvet
19
20 158 Hallmarq, Surrey, UK) and 1.5T (Philips Gyroscan, Guildford, UK) and 1.5 T (Magnetom
21
22 159 Essenza and Symphony, Siemens, Camberley, UK)

23
24
25
26 160 Magnetic resonance protocols varied between institutions. In all cases, these included at least
27
28 161 two orientations (transverse and sagittal) for T2 weighted images (T2WI), one or two
29
30 162 orientations (transverse or dorsal) for T2WI fluid attenuated inversion recovery (FLAIR)
31
32 163 sequences and one or two orientations (transverse and sagittal or dorsal) for T1 weighted
33
34 164 images (T1WI) before and after administration of paramagnetic (gadolinium-based) contrast
35
36 165 medium. In most cases, a transverse-orientation images of gradient echo (GE) T2 * was
37
38 166 obtained.
39

40
41 167 Certain MRI abnormalities were classified as incidental findings. These included minor
42
43 168 anatomical variations that were considered as an implausible cause of epileptic seizures.
44
45 169 These variations included abnormality linked to normal breed variations such as crowding of
46
47 170 the caudal cranial fossa associated to a brachycephalic skull conformation, asymmetry of the
48
49 171 cerebral lateral ventricle (Pivetta and others 2013), arachnoid cysts that were not causing
50
51 172 occipital lobe and cerebellar compression of more than 10% and with associated normal CSF
52
53 173 analysis (Duque and others 2005, MacKillop 2011, Matiasek and others 2007) and finally
54
55 174 MRI abnormalities that were located in areas of the brain inconsistent with the clinical
56
57
58
59
60

1
2
3 175 signs (e.g., neuroanatomical localisation) (Vite and Cross 2011).
4
5

6 176 Other MRI abnormalities were attributed to recently reported epileptic seizures. Such post-
7
8 177 ictal changes have been previously described and consist of diffuse, poorly defined intra-axial
9
10 178 hyperintensity on T2WI and FLAIR images, mainly located in the piriform lobes and
11
12 179 hippocampus with no mass effect and with none or only very mild hyperintensity on T1WI
13
14 180 following contrast administration. These changes were considered to represent a mixture of
15
16 181 cytotoxic oedema and gliosis resulting from epileptic seizures (Kim and others 2001,
17
18 182 Marioni-Henry and others 2012, Mellema and others 1999, Rusbridge and others 2015,
19
20 183 Viitmaa and others 2006). The CSF analysis in these animals were within normal limits.
21
22
23

24
25 184 Statistical analysis was performed using a commercially available computer software (SPSS
26
27 185 Statistic, Version 24, IBM, Armonk, New York).
28
29

30 186 The Fisher's exact test was performed to compare the prevalence of structural lesions
31
32 187 between the three groups of cats (i.e. those aged 1 year old or younger, aged between 1 and 6
33
34 188 years old and older than 6 years). Statistical significance was set at $P < 0.01$, power test
35
36 189 analysis was used to assess whether the groupings used were appropriate to retain statistically
37
38 190 significant findings.
39
40
41

42 191 In addition, a receiver operating characteristic (ROC) analysis was performed on the entire
43
44 192 group of cats to study the optimal cut off age at which prevalence of structural epilepsy
45
46 193 surpassed the prevalence of idiopathic epilepsy.
47
48

49
50 194 Finally, a logistic regression analysis was performed to assess whether age is significantly
51
52 195 associated with the likelihood of suffering from structural epilepsy.
53
54

55 196 Results
56
57
58
59
60

1
2
3 197 A total of 188 cats with epileptic seizures and without interictal neurological deficits
4
5 198 suggestive of primary forebrain disease were included in this study.
6
7 199 Of these, 131/188 (69.7%) presented with a history of generalised tonic-clonic epileptic
8
9 200 seizures and 14 of these had episodes of cluster seizures. A further 9/188 (4.8%) suffered
10
11 201 from focal epileptic seizures that evolved into generalised epileptic seizures (i.e. secondary
12
13 202 generalization). 36/188 (19.2%) cats presented with focal epileptic seizures, 12 of which were
14
15 203 focal epileptic seizures characterised by psychomotor activity (running around the house,
16
17 204 glazed eyes, dilated pupils and aggression). Another 8/188 (4.3%) cats suffered from cluster
18
19 205 of focal epileptic seizures, with oro-facial involvement characterized by salivation, facial
20
21 206 twitching, lip smacking, chewing, licking or swallowing, motor arrest (motionless starring)
22
23 207 and behavioural changes (mainly aggression). Finally, 4/188 (2.1%) cats presented with
24
25 208 feline audiogenic reflex seizures (FARS) characterized by myoclonic jerks that were
26
27 209 triggered by sound, and these epileptic seizures were frequently followed by secondary
28
29 210 generalization.
30
31
32
33
34 211 Neurological deficits in 19 cats were considered representative of post-ictal deficits and had
35
36 212 resolved by a subsequent examination. Post-ictal abnormalities included minor delays in
37
38 213 postural reactions, decreased menace responses, obtunded mentation and behavioural
39
40 214 changes.
41
42
43 215 Classifying the cats according to the age of onset of seizures, 32 (17%) cats were aged or
44
45 216 younger than one year, 91 (48.7%) cats were aged between one and six years and the
46
47 217 remaining 65 (35.6%) cats were older than six years old.
48
49 218 The most represented breed was the domestic short hair cat (77.65 % of the population),
50
51 219 followed by Bengal (3.72%) and Maine Coon (3.2%) breeds. The distribution between males
52
53 220 (55.85%) and females (44.15%) was approximately equal.
54
55
56 221 Magnetic resonance imaging abnormalities were detected in 35/188 cases (18.6%).
57
58
59
60

1
2
3 222 Six MRI abnormalities were classified as “incidental findings”; thus, they were not
4
5 223 considered in the study. These abnormalities included mild crowding of the caudal fossa and
6
7 224 mild lateral ventricle enlargement found in a Persian cat, which may have been caused by
8
9 225 normal breed variations associated with brachycephalic skull conformation; a focal fluid-
10
11 226 filled dilatation within the third ventricle that appeared to be a small arachnoid cyst (Duque
12
13 227 and others 2005, MacKillop 2011, Matiasek and others 2007); a small pituitary mass in a cat
14
15 228 without hypercortisolaemia, insulin-resistant diabetes mellitus, acromegaly or compression
16
17 229 of the surrounding tissue (Sellon and others 2009); and mild dilatation of the left olfactory
18
19 230 recess, without amass effect on the surrounding parenchyma.
20
21

22
23 231 Six further MRI abnormalities were classified as post-ictal. In those cases, deemed to have a
24
25 232 significant finding, the majority of the lesions were located at the level of the piriform lobe (5
26
27 233 cases - 22%), hippocampus (5 cases - 22%) and frontal cortex (5 cases - 22%). A diffuse
28
29 234 cortical distribution was seen in three cases (13%), two had lesions in the olfactory bulb
30
31 235 (8.6%), and there was one example (4.3%) in each of the parietal cortex, temporal cortex and
32
33 236 in the lateral and medial geniculate nuclei.
34
35

36 237 Subdividing the animals according to age (figure 1), structural MRI abnormalities were found
37
38 238 in 3/32 (9.4%) cats aged or younger than one year old. In one case, an abnormal sulcal
39
40 239 pattern was observed at the level of the left temporal lobe and resulted in blurring of the
41
42 240 white-grey matter junction and T2WI hyperintensity within the white and grey matter. The
43
44 241 CSF analysis was within normal limits, and the lesion was suspected likely caused by a
45
46 242 disorder of the temporal cortex formation (cortical dysplasia). In the other two cases, two
47
48 243 small lesions CSF-filled cavities were observed within the brain; these had the imaging
49
50 244 characteristics of CSF. In one case, the lesion was located at the level of the interventricular
51
52 245 foramen and in direct contact with the ventricular system and in the second case the lesion
53
54 246 was located at the level of the right frontal lobe, within the brain parenchyma and in direct
55
56
57
58
59
60

1
2
3 247 contact with the subarachnoid space. In both cases, the CSF analysis was within normal
4
5 248 limits.
6
7 249 In the cats aged between 1 and 6 years, 5/91 (5.5%) had significant lesions on MRI (figure 2).
8
9 250 Two cases presented with MRI changes that consisted of bilateral hippocampal T1WI
10
11 251 hypointensity and T2WI hyperintensity with mild heterogeneous post-contrast hyperintensity
12
13 252 on T1WI. In these cases, feline hippocampal necrosis was suspected. In each of the three
14
15 253 other cases, there was a single small lesion with the imaging characteristics of CSF and no
16
17 254 mass effect. In one, this was a small, well defined, wedge shaped lesion in the left occipital
18
19 255 lobe, at the white-grey matter junction. This was suspected to be an ischemic lesion. In
20
21 256 another, the lesion was at the rostral aspect of the calvarium and was suspected to be a
22
23 257 congenital malformation. In the final case, there was a single well defined lesion in the right
24
25 258 temporal lobe: this cat has a history of trauma a few months previously and this was felt to be
26
27 259 the result of a brain injury.
28
29
30
31 260 Of the cats older than six years at seizure onset, 15/ 65 (23.1%) had a significant structural
32
33 261 MRI abnormality (figure 3). These abnormalities included suspected neoplastic lesions
34
35 262 (seven cases), of which five were intra-axial. These were well defined lesions in the piriform
36
37 263 lobe, which were hyperintense in T2WI and FLAIR and isointense in T1WI with mild or no
38
39 264 enhancement following contrast administration. These lesions were suspected to be gliomas.
40
41 265 The remaining two neoplastic lesions were extra-axial with a wide meningeal base,
42
43 266 homogeneous contrast enhancement and dural tail signs, moderate perilesional oedema, a
44
45 267 mass effect on the surrounding brain parenchyma and secondary bone hyperostosis. These
46
47 268 lesions were suspected to be meningiomas. In three cases, there was bilateral enlargement of
48
49 269 the CSF spaces, most noticeable at the level of the sulci of the fronto-parietal lobes. These
50
51 270 lesions were suspected to be related to cortical brain degeneration and age. Hippocampal
52
53 271 necrosis, as defined previously, was suspected in two cases. In one case, intra-axial bilateral
54
55
56
57
58
59
60

1
2
3 272 and symmetrical lesions were noted in the lateral and medial geniculate nuclei; these were
4
5 273 hyperintense on T2WI and hypointense on T1WI. These lesions did not cause any
6
7 274 perilesional oedema or mass effect and they were felt likely to be the result of a metabolic
8
9 275 encephalopathy. A case of acquired meningoencephalocoele at the level of the parietal lobe
10
11 276 and above calvaria was seen in a cat with a history of trauma. Finally, one cat had two small
12
13 277 circular intra-axial lesions; these were hypointense on T1WI, T2WI and GET2* and were felt
14
15 278 to be consistent with cerebral haemorrhages.
16
17

18 279 Statistical comparison of the number of clinically significant lesions on MRI in the different
19
20 280 age groups showed that the proportion of idiopathic / structural epilepsy is not the same
21
22 281 among the groups (Fisher's exact test, $p < 0.01$) with the only significant difference in the
23
24 282 proportion of idiopathic / structural epilepsy seen between group 2 (cats aged between 1-6
25
26 283 years) and group 3 (cats older than 6 years) (table 1 $p = 0.005$). There is no difference in
27
28 284 prevalence between the other groups, although the number of cases in these groups make any
29
30 285 comparison underpowered to detect a significant difference (power 5% when comparing
31
32 286 group 1 with group 2; power 14% when comparing group 1 with group 3).
33
34
35

36 287 Therefore, to investigate if the likelihood of cats suffering from structural epilepsy is
37
38 288 correlated with their age, the cats belonging to group 1 and 2 were combined and the Fisher's
39
40 289 exact test was applied between these newly formed groups (group 1 those 6 years old or
41
42 290 younger and group 2 those older than 6 years old). Results indicated that the prevalence of
43
44 291 structural epilepsy is significantly higher (Fisher's exact test, $p < 0.01$) in the group 2 (cat
45
46 292 older than 6 years) with a sample size sufficient to achieve 86% power and with a
47
48 293 significance of type-1 error $\alpha = 0.05$ (table 2 $p = 0.002$).
49
50

51 294 The ROC analysis indicated that age is a moderately good discriminator between statuses.
52
53 295 The area under the ROC curve (AUC) was 0.66 indicating an optimal cut-off at 5 years old
54
55 296 (accuracy 74%, specificity 75%, sensitivity 65%). (figure 4)
56
57
58
59
60

1
2
3 297 The logistic regression analysis showed that age is significantly associated with the
4
5 298 possibility of suffering from structural epilepsy ($p < 0.01$) with the likelihood of suffering
6
7 299 from a structural brain disease increasing 14% per year. (table 3)
8

9
10 300 Discussion

11 301 The present study describes the diagnostic findings in a population of cats presenting with
12
13 302 seizures but with no evidence of forebrain dysfunction on neurological examination.
14

15
16 303 The findings of this study show that MRI is useful to detect lesions in clinically silent regions
17
18 304 of the brain in both young and old cats and indicate that lesions are more prevalent in cats
19
20 305 greater than six years of age. This is similar to findings in dogs and appears to reflect an
21
22 306 increased risk of brain neoplasia with age. By undertaking ROC analysis, we were further
23
24 307 able to show that five years appears a more suitable cut off age at which prevalence of
25
26 308 structural epilepsy surpassed the prevalence of idiopathic epilepsy.
27
28

29 309 Although our data are inconsistent with the traditional anecdotal impression that the
30
31 310 prevalence of epilepsy of unknown origin in cats has been overestimated because of the
32
33 311 inconsistent application of MRI (Barnes 2004, Pakozdy and others 2010, Schriefl and others
34
35 312 2008), our findings fits well with the assumption that animals with congenital structural brain
36
37 313 anomalies usually develop problems within the first year (Bagley 2005), because 9.4% of cats
38
39 314 aged or younger than 1 year old diagnosed with structural epilepsy showed MRI changes
40
41 315 suggestive of congenital malformation.
42
43

44
45 316 Cats without identifiable lesions are usually diagnosed with probable structural epilepsy
46
47 317 (Barnes and others 2004, Platt 2001, Quesnel and others 1997, Thomas 2010). However, the
48
49 318 alternative hypothesis is that some of these individuals have idiopathic epilepsy.
50
51

52
53 319 The prevalence of structural epilepsy in this study is 12.2% (23/188 cases). This prevalence is
54
55 320 low when compared to other previous published studies (Barnes and others 2004, Pakoszy
56
57 321 and others 2010, Schrief and others 2008, Whale and others 2014) in which structural
58
59
60

1
2
3 322 epilepsy was observed in 41% to 62% of cats.
4
5

6 323 This difference is most likely due to the inclusion criteria of our study. These were restricted
7
8 324 to cats with a normal interictal physical and neurological examination whereas in the
9
10 325 previous studies inclusion criteria included cats presenting with reactive seizures and/or
11
12 326 neurological deficits and therefore more susceptible to structural brain lesions.
13
14

15
16 327 The MRI scanners used in this study included 1 and 1.5 T superconducting electromagnets
17
18 328 (used in around 50% of cases) and a 0.4 T permanent magnet and although the images
19
20 329 obtained using high field (>1T) magnets are excellent for identifying both large and subtle
21
22 330 structural lesions, it remains possible that the group of cats undergoing low field MRI had
23
24 331 subtle structural lesions that were not detected. However, in the 99 cats that underwent high
25
26 332 field MRI, subtle lesions identified that would have been missed with low field MRI were not
27
28 333 identified. Therefore, the proportion of cats in which a subtle lesion might have been missed
29
30 334 by a low field MRI was likely negligible.
31
32
33

34
35 335 The conclusions of this study are similar to those in previous studies in dogs (Armasu and
36
37 336 others 2014, De Risio and others 2015, Schwartz and others 2013, Smith and others 2008)
38
39 337 which demonstrated that the age at seizure onset and neurological examination findings were
40
41 338 both significantly associated with the type of brain disease, with our results indicating, the
42
43 339 odds ratio of structural disease increasing of 14% per year of life.
44
45

46 340 Another interesting finding in this study that is similar to the finding of studies previously
47
48 341 conducted in dogs (Schwartz and others 2011, Smith and others 2008) was that most of the
49
50 342 lesions (73.91%) were located in the olfactory, frontal and pyriform lobes, and the
51
52 343 hippocampus. Although dysfunction in these areas is less likely to cause neurological
53
54 344 deficits, lesions located in these area could act as strong epileptogenic foci because of the
55
56 345 widespread connections to the limbic system.
57
58
59
60

1
2
3 346 The cases analysed in this study involved a large population of cats widely distributed
4
5 347 throughout the United Kingdom (UK). It is therefore expected to be a good representation of
6
7 348 the cats with epileptic seizures and normal interictal examinations in the UK. Extrapolation
8
9 349 of these results to cats outside of the UK will have to take into consideration any
10
11 350 geographical differences in common feline seizure aetiology, in particular variations in
12
13 351 prevalence of infectious diseases and their ability to result in seizures without interictal
14
15 352 changes.
16
17
18

19 353 Sources of potential controversy associated with this study include the definition of an
20
21 354 abnormal neurological examination and the definition of clinically significant lesions on
22
23 355 MRI. These decisions were made with clinical practice in mind and neurological deficits
24
25 356 were always deemed important if they were indicative of forebrain dysfunction.
26
27

28 357 The classification of MRI changes as post-ictal is also open to question. We based our
29
30 358 interpretation of such changes on previous studies that demonstrate hyperintensity on T2WI
31
32 359 and FLAIR imaging following seizures, particularly in the hippocampus and pyriform lobe
33
34 360 (Kim and others 2001, Marioni-Henry and others 2012, Mellema and others 1999, Viitmaa
35
36 361 and others 2006). It was recently postulated that such MRI changes in the hippocampus and
37
38 362 associated extra-hippocampal regions could represent necrosis secondary to immune-
39
40 363 mediated limbic encephalitis with voltage-gated potassium channel (VGKC) complex
41
42 364 antibodies (Fatzer and others 2000, Pakozdy and others 2013, Pakozdy and others 2011,
43
44 365 Schmied and others 2008). Although we found no CSF abnormalities in cases defined as
45
46 366 having post-ictal changes, it is difficult to be certain whether borderline T2 hyperintensity of
47
48 367 the hippocampus and parahippocampal structures represents the cause (Fatzer and others
49
50 368 2000, Pakozdy and others 2013, Pakozdy and others 2011, Schmied and others 2008) or
51
52 369 consequence of the epileptic seizures (Marioni-Henry and others 2012). To avoid incorrect
53
54 370 classification of these cases, the criteria suggested by Wahle (Wahle and others 2014) were
55
56
57
58
59
60

1
2
3 371 followed, whereby cats were considered to have hippocampal necrosis only if confirmed by
4
5 372 conclusive MRI criteria and the occurrence of treatment-resistant complex partial seizures
6
7 373 with orofacial involvement (Wahle and others 2014). Cats classified as having post-ictal
8
9 374 changes did not meet these criteria.

10
11 375 In addition to the cases mentioned above, four cats older than six years had a history of
12
13 376 myoclonic jerks that typically progressed to generalised epileptic seizures and were triggered
14
15 377 by high frequency sounds. Although MRI and CSF analysis of these animals were within
16
17 378 normal limits and seizures were well controlled on medical treatment, these cats may be
18
19 379 suffering from a syndrome known as feline audiogenic reflex seizures (FARS), which has a
20
21 380 geriatric onset and suspected degenerative aetiology (Lowrie and others 2016). In the absence
22
23 381 of MRI changes, we classified the animals belonging to this group as having epilepsy of
24
25 382 unknown origin.

30 383 Conclusion

31
32
33 384 In the absence of systemic disease that might trigger seizures, epileptic cats that are
34
35 385 neurologically normal in the interictal period present a significantly increased likelihood of
36
37 386 having an identifiable abnormality on MRI if they are older than 5 years old. Although
38
39 387 histopathological confirmation was not possible in most cases in the current study, a large
40
41 388 number of these lesions were considered to represent neoplasia. Identifying such lesions is
42
43 389 crucial for determining the optimal treatment, and owners of cats in this age group should be
44
45 390 strongly encouraged to pursue further investigation.

46
47
48 391

49
50
51 392

52
53
54 393

394 REFERENCES

- 395 BERENDT, M., FARQUHAR, R. G., MANDIGERS, P. J. J., PAKOZDY, A., BHATTI, S.
396 F. M., DE RISIO, L. & OTHERS (2015) International veterinary epilepsy task force
397 consensus report on epilepsy definition, classification and terminology in companion
398 animals. *Vet Res* 11, 182.
- 399 BERG AT & SCHEFFER IE. (2011) New concepts in classification of the epilepsies:
400 entering the 21st century. *Epilepsia* 52, 1058-1062.
- 401 FINNERTY EK, BARNES HELLER HL, MERCIER MN. GIOVANELLA CJ, VIVIAN
402 WL & RYLANDER H (2014) Evaluation of therapeutic phenobarbital concentrations and
403 application of a classification system for seizures in cats: 30 cases (2004–2013). *J Am Vet*
404 *Med Assoc* 244, 195-199.
- 405 MUNANA KR (2013) Update: Seizure Management in Small Animal Practice. *Vet Clin*
406 *North Am Small Anim Pract* 43, 1127-1147.
- 407 PAKOZDY A, HALASZ P & KLANG A (2014) Epilepsy in cats: Theory and Practice. *J*
408 *Vet Intern Med* 28, 255-263.
- 409 WAHLE AM, BRUHSCHWEIN A, MATIASEK K, PUTSCHBACH K, WAGNER E,
410 MUELLER RS & OTHERS (2014) Clinical characterization of Epilepsy of Unknown Cause
411 in cats. *J Vet Intern Med* 28, 182-188.
- 412 BAILEY KS & DEWEY CW (2009) The seizuring cat Diagnostic work-up and therapy. *J*
413 *Feline Med Surg* 11, 385-394.
- 414 DE RISIO L, BHATTI S, MUNANA K, PENDERIS J, STEIN V, TIPOLD A & OTHERS
415 (2015) International veterinary epilepsy task force consensus proposal: diagnostic approach

- 1
2
3 416 to epilepsy in dogs. *Vet Res* 11, 148.
4
5
6 417 RUSBRIDGE C (2005) Diagnosis and control of epilepsy in the cat. *In Practice* 27, 208–214.
7
8
9 418 SCHWARTZ M, LAMB CR, BRODBELT DC & VOLK HA (2011) Canine intracranial
10
11 419 neoplasia: clinical risk factors for development of epileptic seizures. *J Small Anim Pract* 52,
12
13 420 623- 627.
14
15
16
17 421 SMITH PM, TALBOT CE & JEFFERY ND (2008) Findings on low-field cranial MR images
18
19 422 in epileptic dogs that lack interictal neurological deficits. *Vet J* 176, 320–325.
20
21
22 423 ARMASU M, PACKER RM, COOK S, SOLCAN G & VOLK HA (2014) An exploratory
23
24 424 study using statistical approach as a platform for clinical reasoning in canine epilepsy. *Vet J*
25
26 425 202, 292-296.
27
28
29
30 426 SCHWARTZ M, MUNANA KR & NETTIFEE-OSBORNE J (2013) Assessment of the
31
32 427 prevalence and clinical features of cryptogenic epilepsy in dogs: 45 cases (2003-2011) *J Am*
33
34 428 *Vet Med Assoc* 42, 651-657.
35
36
37
38 429 BAGLEY RS, GAVIN PR, MOORE MP, SILVER GM & HARRINGTON ML (1999)
39
40 430 Clinical signs associated with brain tumors in dogs: 97 cases (1992-1997) *J Am Vet Med*
41
42 431 *Assoc* 215, 818-819.
43
44
45 432 CAMERON S, RISHNIW M, MILLER AD, STURGES B & DEWEY CW (2015)
46
47 433 Characteristics and Survival of 121 Cats Undergoing Excision of Intracranial Meningiomas
48
49 434 (1994-2011) *Vet Surg* 44, 772-776.
50
51
52 435 SNYDER JM, SHOFR FS, VAN WINKLE TJ & MASSICOTTE C. (2006) Canine
53
54 436 intracranial primary neoplasia: 173 cases (1986-2003). *J Vet Intern Med* 12, 669-675.
55
56
57 437 TOMEK A, CIZINAUSKAS S, DOHER M, GANDINI G & JAGGY A. (2006) Intracranial
58
59
60

- 1
2
3 438 neoplasia in 61 cats: localisation, tumour types and seizure patterns. *J Feline Med Surg* 8,
4
5 439 243-253.
6
7
8 440 TROXEL MT, VITE CH, VAN WINKLE TJ, NEWTON AL, TICHES D, DAYRELL-
9
10 441 HART B & OTHERS (2003) Feline intracranial neoplasia: retrospective review of 160 cases
11
12 442 (1985-2001). *J Vet Intern Med* 17, 850-859.
13
14
15 443 PIVETTA M, DE RISIO L, NEWTON R & DENNIS R (2013) Prevalence of lateral
16
17 444 ventricle asymmetry in brain MRI studies of neurologically normal dogs and dogs with
18
19 445 idiopathic epilepsy. *Vet Radiol Ultrasound* 54, 516-521.
20
21
22 446 DUQUE C, PARENT J, BRISSON B, DA COSTA R & POMA R (2005) Intracranial
23
24 447 arachnoid cysts: are they clinically significant? *J Vet Inter Med* 19,772-774.
25
26
27 448 MACKILLOP E (2011) Magnetic Resonance Imaging of intracranial malformation in dogs
28
29 449 and cats. *Vet Radiol Ultrasound* 52, Supp.1 S42-S51.
30
31
32 450 MATIASEK LA, PLATT SR, SHAW S & DENNIS R (2007) Clinical and magnetic
33
34 451 resonance imaging characteristics of quadrigeminal cysts in dogs. *J Vet Intern Med* 21, 1021-
35
36 452 1026.
37
38
39 453 VITE CH & CROSS JR (2011) Correlating magnetic resonance findings with
40
41 454 neuropathology and clinical signs in dogs and cats. *Vet Radiol Ultrasound*, 52 Supp. 1, S23-
42
43 455 S31.
44
45
46 456 KIM, JA, CHUNG, JI, YOON, PH, KIM DI, CHUNG TS, KIM EJ & OTHERS (2001)
47
48 457 Transient MR signal changes in patients with generalized tonicoclonic seizure or status
49
50 458 epilepticus: periictal diffusion- weighted imaging. *AJNR* 22, 1149-1160.
51
52
53
54
55 459 MARIONI-HENRY K, MONTEIRO R & BEHR S (2012) Complex partial orofacial seizures
56
57
58
59
60

- 1
2
3 460 in English cats. *Vet Rec* 170, 471.
4
5
6 461 MELLEMA LM, KOBLIK PD, KORTZ GD, LECOUTEUR RA, CHECHOWITZ MA &
7
8 462 DICKINSON PJ (1999) Reversible magnetic resonance imaging abnormalities in dogs
9
10 463 following seizures. *Vet Radiol Ultrasound* 40, 588–595.
11
12
13 464 RUSBRIDGE C, LONG S, JOVANOVIK J, MILNE M, BERENDT M, BHATTI SFM &
14
15 465 OTHERS (2015) International Veterinary Epilepsy Task Force recommendations for a
16
17 466 veterinary epilepsy-specific MRI protocol. *Vet Res* 11, 194.
18
19
20
21 467 VIITMAA R, CIZINAUSKAS S, BERGAMASCO LA, KUUSELA E, PASCOE P, TEPP
22
23 468 AM & OTHERS (2006) Magnetic resonance imaging findings in Finnish Spitz dogs with
24
25 469 focal epilepsy. *J Vet Inter Med* 20, 305– 310.
26
27
28
29 470 SELTON RK, FIDEL J, HOUSTON R & GAVIN PR (2009) Linear- Accelerator –Based
30
31 471 Modified Radiosurgical Treatment of Pituitary Tumors in Cats: 11 cases (1997-2008) *J Vet*
32
33 472 *Intern Med* 23, 1038-104.
34
35
36
37 473 BARNES HL, CHRISMAN CL, MARIANI CL, SIMS M & ALLEMAN AR (2004) Clinical
38
39 474 signs, underlying cause, and outcome in cats with seizures: 17 cases (1997–2002). *J Am Vet*
40
41 475 *Med Assoc* 225,1723–1726.
42
43
44 476 PAKOZDY A, LESCHNIK M, SARCHAHI AA, TICHY AG & THALHAMMER JG
45
46 477 (2010) Clinical comparison of primary versus secondary epilepsy in 125 cats. *J Feline Med*
47
48 478 *Surg* 12, 910-6.
49
50
51 479 SCHRIEFL S, STEINBERG TA, MATIASEK K, OSSIG A, FENSKE N & FISCHER A
52
53 480 (2008) Etiologic classification of seizures, signalment, clinical signs, and outcome in cats
54
55 481 with seizure disorders: 91 cases (2000–2004). *J Am Vet Med Assoc* 233, 1591–1597.
56
57
58
59
60

- 1
2
3 482 BAGLEY RS (2005). Clinical evaluation and management of animals with seizures. In:
4
5 483 Bagley, R.S. (Ed.), *Fundamentals of Veterinary Clinical Neurology*. Blackwell Publishing,
6
7 484 Ames, 363–376.
8
9
10 485 PLATT SR (2001) Pearls of Veterinary Practice. Feline Seizure Control. *J Am Anim Hosp*
11
12 486 *Assoc* 37,515-517.
13
14
15 487 QUESNEL AD, PARENT JM, MCDONNELL W, PERCY D & LUMSDEN JH (1997)
16
17 488 Diagnostic evaluation of cats with seizures disorders: 30 cases (1991-1993) *J Am Vet Med*
18
19 489 *Assoc* 210, 65-71.
20
21
22
23 490 THOMAS WB (2010) Idiopathic Epilepsy in Dogs and Cats. *Vet. Clin. Small. Anim* 40, 161-
24
25 491 179.
26
27
28 492 FATZER R, GANDINI G, JAGGY A, DOHERR M & VANDEVELDE M (1990) Necrosis
29
30 493 of hippocampus and piriform lobe in 38 domestic cats with seizures: A retrospective study on
31
32 494 clinical and pathologic findings. *J Vet Intern Med* 4:26-39.
33
34
35
36 495 PAKOZDY A, HALASZ P, KLANG A, BAUER J, LESCHNIK M, TICHY A & OTHERS
37
38 496 (2013) Suspected limbic encephalitis and seizure in cats associated with voltage-gated
39
40 497 potassium channel (VGKC) complex antibody. *J Vet Intern Med* 27, 212–214.
41
42
43
44 498 PAKOZDY A, GRUBER A, KNEISSL S, LESCHNIK M, HALASZ P & THALHAMMER
45
46 499 JG (2011) Complex partial cluster seizures in cats with orofacial involvement. *J Feline Med*
47
48 500 *Surg* 13, 687–693.
49
50
51 501 SCHMIED O, SCHARF G, HILBE M, MICHAL U, TOMSA K & STEFFEN F (2008)
52
53 502 Magnetic resonance imaging of feline hippocampal necrosis. *Vet Radiol Ultrasound* 49,343-
54
55 503 349
56
57
58
59
60

1
2
3 504 LOWRIE M, BESSANT C, HARVEY RJ, SPARKES A & GAROSI L (2016) Audiogenic
4
5 505 reflex seizures in cats. *J Feline Med Surg* 18,328-33.
6
7
8
9 506
10
11 507
12
13
14 508
15
16
17
18 509
19
20
21 510
22
23
24 511
25
26
27 512
28
29
30
31 513
32
33
34 514
35
36
37 515
38
39
40 516
41
42
43 517
44
45
46 518
47
48
49 519
50
51
52 520
53
54
55
56 521
57
58
59
60

Confidential: For Review Only

522 FIGURES

523 Figure 1. Graph showing the number of cats with normal (black) and structural (grey) MRI
524 abnormalities in different age groups.

525

526 Figure 2. Graph showing the aetiology of structural epilepsy in cats aged between 1 to 6 years
527 old.

528

529 Figure 3. Graph showing the aetiology of structural epilepsy in cats older than 6 years old.

530

531 Figure 4. Receiver Operating Characteristic (ROC) analysis: The area under the ROC curve
532 (AUC) was 0.66 indicating that age is a moderately good discriminator between statuses).

533 The optimal cut-off is 5 years old (accuracy 74%, specificity 75%, sensitivity 65%).

534 Table 1

535 Fisher's Exact test between the 3 groups of age: group 1 cats aged 1 years old or younger,
536 group 2 cats older than 1 years old and aged 6 years old or younger, group 3 cats older than 6
537 years. The proportion of idiopathic / structural epilepsy is not the same among the groups
538 (Fisher's exact test, $p < 0.01$). Further analysis performed between different pairings of these 3
539 groups is represented by the letters in subscript. Each subscript letter (a, b) denoted a subset
540 of 2 Groups whose proportion do not differ significantly from each other at 0.01 level (group
541 1 and group 3 (a) and group 1 and group 2 (b)). The only significant difference in the
542 proportion idiopathic / structural epilepsy is between the group 2 (b) and group 3 (a). The
543 proportion in group 1, instead do not differ significantly from the group 2 (b) and the group 3
544 (a)

1
2
3 545 Table 2
4
5

6 546 Fisher's Exact test between 2 groups of age: group 1 cats aged 6 years old or younger, group
7
8 547 2 cats older than 6 years old. The prevalence of structural epilepsy is significantly higher
9
10 548 (Fisher's exact test, $p < 0.01$) in the group 2 (cat older than 6 years). The sample is sufficient
11
12 549 to achieve 86% power with a significance of type-1 error $\alpha = 0.05$
13
14

15
16 550
17
18

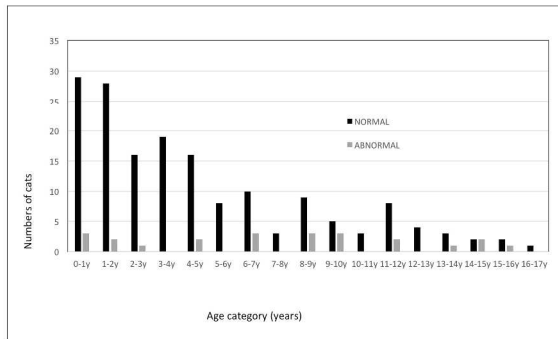
19 551 Table 3.
20

21 552 Logistic Regression Analysis indicating that age is significantly associated with the event of
22
23 553 suffering from structural epilepsy ($p < 0.01$). Odds ratio for age is 1.14 (confidence interval
24
25 554 1.04-1.26), this means that the likelihood of structural disease increases 14%/year.
26
27

28 555
29
30
31
32
33
34
35
36
37
38
39
40
41
42
43
44
45
46
47
48
49
50
51
52
53
54
55
56
57
58
59
60

1
2
3
4
5
6
7
8
9
10
11
12
13
14
15
16
17
18
19
20
21
22
23
24
25
26
27
28
29
30
31
32
33
34
35
36
37
38
39
40
41
42
43
44
45
46
47
48
49
50
51
52
53
54
55
56
57
58
59
60

AGE PREVALENCE	NORMAL	ABNORMAL
0-1y	29	3
1-2y	28	2
2-3y	16	1
3-4y	19	0
4-5y	16	2
5-6y	8	0
6-7y	10	3
7-8y	3	0
8-9y	9	3
9-10y	5	3
10-11y	3	0
11-12y	8	2
12-13y	4	0
13-14y	3	1
14-15y	2	2
15-16y	2	1
16-17y	1	0

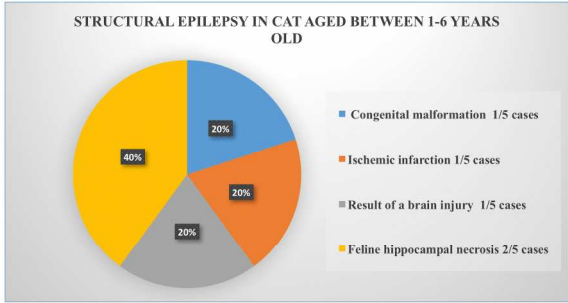


Graph showing the number of cats with normal (black) and structural (grey) MRI abnormalities in different age groups.

figure 1
541x304mm (225 x 225 DPI)

or Review Only

1
2
3
4
5
6
7
8
9
10
11
12
13
14
15
16
17
18
19
20
21
22
23
24
25
26
27
28
29
30
31
32
33
34
35
36
37
38
39
40
41
42
43
44
45
46
47
48
49
50
51
52
53
54
55
56
57
58
59
60

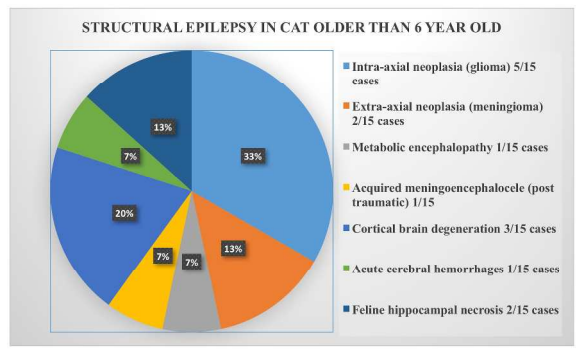


Graph showing the aetiology of structural epilepsy in cats aged between 1 to 6 years old.

figure 2
376x211mm (300 x 300 DPI)

Or Review Only

1
2
3
4
5
6
7
8
9
10
11
12
13
14
15
16
17
18
19
20
21
22
23
24
25
26
27
28
29
30
31
32
33
34
35
36
37
38
39
40
41
42
43
44
45
46
47
48
49
50
51
52
53
54
55
56
57
58
59
60

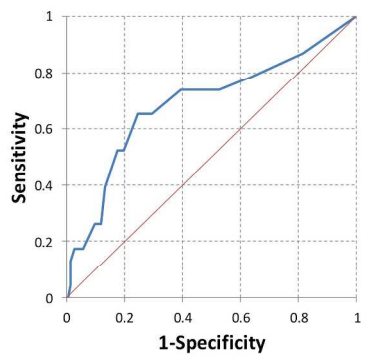


Graph showing the aetiology of structural epilepsy in cats older than 6 years old.

541x304mm (225 x 225 DPI)

For Review Only

1
2
3
4
5
6
7
8
9
10
11
12
13
14
15
16
17
18
19
20
21
22
23
24
25
26
27
28
29
30
31
32
33
34
35
36
37
38
39
40
41
42
43
44
45
46
47
48
49
50
51
52
53
54
55
56
57
58
59
60



Receiver Operating Characteristic (ROC) analysis: The area under the ROC curve (AUC) was 0.66 indicating that age is a moderately good discriminator between statuses). The optimal cut-off is 5 years old (accuracy 74%, specificity 75%, sensitivity 65%).

figure 4
541x304mm (225 x 225 DPI)

For Review Only

Age	Idiopathic Epilepsy	Structural Epilepsy	Total
Group 1: age ≤ 1 y	29 ^{a,b}	3 ^{a,b}	32
Group 2: age between 1-6 y	86 ^b	5 ^b	91
Group 3: age >6 y	50 ^a	15 ^a	65
Total	165	23	188
Fisher's Exact Test 0.005			

Fisher's Exact test between the 3 groups of age: group 1 cats aged 1 years old or younger, group 2 cats older than 1 years old and aged 6 years old or younger, group 3 cats older than 6 years. The proportion of idiopathic / structural epilepsy is not the same among the groups (Fisher's exact test, $p < 0.01$). Further analysis performed between different pairings of these 3 groups is represented by the letters in subscript. Each subscript letter (a, b) denoted a subset of 2 Groups whose proportion do not differ significantly from each other at 0.01 level (group 1 and group 3 (a) and group 1 and group 2 (b)). The only significant difference in the proportion idiopathic / structural epilepsy is between the group 2 (b) and group 3 (a). The proportion in group 1, instead do not differ significantly from the group 2 (b) and the group 3 (a)

table 1
1693x952mm (72 x 72 DPI)

1
2
3
4
5
6
7
8
9
10
11
12
13
14
15
16
17
18
19
20
21
22
23
24
25
26
27
28
29
30
31
32
33
34
35
36
37
38
39
40
41
42
43
44
45
46
47
48
49
50
51
52
53
54
55
56
57
58
59
60

Age	Idiopathic epilepsy	Structural epilepsy	Total
Group 1: <=6	115	8	123
Group 2: >6	50	15	65
Total	165	23	188
Fisher's exact Test 0.002			

Fisher's Exact test between 2 groups of age: group 1 cats aged 6 years old or younger, group 2 cats older than 6 years old. The prevalence of structural epilepsy is significantly higher (Fisher's exact test, $p < 0.01$) in the group 2 (cat older than 6 years). The sample is sufficient to achieve 86% power with a significance of type-1 error $\alpha = 0.05$

table 2
1693x952mm (72 x 72 DPI)

Review Only

1
2
3
4
5
6
7
8
9
10
11
12
13
14
15
16
17
18
19
20
21
22
23
24
25
26
27
28
29
30
31
32
33
34
35
36
37
38
39
40
41
42
43
44
45
46
47
48
49
50
51
52
53
54
55
56
57
58
59
60

	B	Sig.	Exp(B)	95% C.I. for EXP(B)	
				Lower	Upper
Age	.135	.006	1.144	1.040	1.259
Constant	-2.708	.000	.067		

Logistic Regression Analysis indicating that age is significantly associated with the event of suffering from structural epilepsy ($p < 0.01$). Odds ratio for age is 1.14 (confidence interval 1.04-1.26), this means that the likelihood of structural disease increases 14%/year.

table 3
1693x952mm (72 x 72 DPI)

For Review Only