



Bradbury, C. (2018). Sequence analysis of exon 1 of the ferritin light chain (FTL) gene can reveal the rare disorder 'hereditary hyperferritinaemia without cataracts'. *British Journal of Haematology*. Advance online publication. <https://doi.org/10.1111/bjh.15231>

Peer reviewed version

Link to published version (if available):
[10.1111/bjh.15231](https://doi.org/10.1111/bjh.15231)

[Link to publication record in Explore Bristol Research](#)
PDF-document

This is the author accepted manuscript (AAM). The final published version (version of record) is available online via WILEY at <https://onlinelibrary.wiley.com/doi/abs/10.1111/bjh.15231> . Please refer to any applicable terms of use of the publisher.

University of Bristol - Explore Bristol Research

General rights

This document is made available in accordance with publisher policies. Please cite only the published version using the reference above. Full terms of use are available:
<http://www.bristol.ac.uk/red/research-policy/pure/user-guides/ebr-terms/>

Hyperferritinaemia is a common issue for clinicians and the associated diagnosis can often remain obscure particularly when the transferrin saturation is normal and *HFE* gene testing is not therefore the immediate route. Raised serum ferritin concentrations are not specific although they may represent iron overload (Worwood, 1990). A persistently raised ferritin without an immediate cause, for example inflammation, malignancy or hepatocyte damage, could signify one of several rare genetic disorders of iron metabolism. When investigating isolated hyperferritinaemia, *ferroportin* gene sequencing may be considered, particularly where there is evidence of Kupffer cell iron on biopsy and/or splenic iron overload on magnetic resonance imaging (MRI) (Pietrangelo, 2004). 'Hereditary hyperferritinaemia cataract syndrome' (HHCS) is a well-documented condition in which patients develop cataracts at an early age (Millonig *et al*, 2010). Inheritance is autosomal dominant, and substitution mutations in the IRE (iron response element) 5' untranslated region (UTR) of the ferritin light chain (*FTL*) gene lead to unregulated synthesis of L-ferritin (Beaumont *et al*, 1995). Cataracts are the only proven clinical manifestation of HHCS and are caused by accumulation of L-ferritin in the lens.

Inherited hyperferritinaemia without any obvious clinical manifestations is only sparsely described in the literature. Three heterozygous mutations in exon 1 of the *FTL* gene have been associated with benign hyperferritinaemia where cataracts were absent. A case series was described where the p.(Thr30Ile) mutation was identified in a cohort of French families (Kannengiesser *et al*, 2009). Two further pathogenic mutations - p.(Ala27Val) and p.(Gln26Ile) - have been reported separately (Thurlow *et al*, 2012). These three mutations are associated with higher than normal serum ferritin glycosylation. With the advent of *FTL* gene testing, either directly or via a next generation approach, we sought to characterise all cases that have been identified in the UK with hyperferritinaemia specifically associated with these rare exon 1 mutations.

Selected patients with unexplained hyperferritinaemia and normal transferrin saturation were investigated for the possibility of exon 1 mutations in the *FTL* gene (Cambridge and Oxford laboratories). C282Y homozygosity for *HFE* and ferroportin mutations had been excluded. 20 individuals, comprising 12 probands and 8 relatives (3 unaffected), underwent *FTL* promoter and exon 1 sequencing either directly or via a next generation approach (*see online supplementary material*). No patient had early cataracts and accordingly all 5'UTR sequences were wild-type. The 17 affected individuals associated with either one of the previously described p.(Thr30Ile) or p.(Ala27Val) mutations (Table 1). The cohort comprised 9 males and 8 females (age range 20 to 68 years). All males had a serum ferritin >980mcg/L and mean ferritin values were 1163mcg/l in females and 2012mcg/l in males.

9 of the 17 patients had hepatic iron content evaluated by MRI, with 8 demonstrating no evidence of iron overload (Table 1). The MRI of one patient (no. 9), a 38 year lean non-drinking male, showed evidence of mild hepatic iron loading (2.9mg/g, normal range <1.2mg/g) - this subject was negative for all other known haemochromatosis-associated

mutations via exome sequencing. A subsequent Fibroscan demonstrated no evidence of fibrosis (4.9kPa). Interestingly, the 68 year old father in this family (FTL_6) had haemochromatosis-type arthropathy on hand x-rays. No other affected individuals displayed any characteristic clinical signs or symptoms of iron overload. The heterozygous c.89C>T, p.(Thr30Ile) mutation occurred in 3 families and 8 isolated individuals (Figure 1). The heterozygous c.80C>T, p.(Ala27Val) variant was present in a fourth family (FTL_6). Co-segregation of the mutation was observed and inheritance was consistent with autosomal dominant transmission.

8 of the 17 patients underwent therapeutic venesection in response to their hyperferritinaemia and 4 developed iatrogenic anaemia (Table 1). One patient (no. 11) developed symptomatic anaemia (Hb 81g/L from 144 g/L) following venesection. Only one patient (no. 17) underwent perhaps appropriate venesection as she was also a compound heterozygote (C282Y/H63D) for *HFE*.

The p.(Thr30Ile) and p.(Ala27Val) pathogenic variants of the *FTL* gene are relatively rare findings each with only a single publication in the literature to date. The disorder is part of OMIM classification 'hyperferritinaemia with or without cataracts' (#600886). We found the p.(Thr30Ile) mutation explained the majority of cases. There was no evidence of iron overload in these individuals as in the French series of families with the same mutation (Kannengiesser *et al*, 2009). The p.(Ala27Val) variant was present in a single family (FTL_6) where all affected individuals had a serum ferritin of at least 2000mcg/L. The male affected sibling had evidence of mild iron overload on MR imaging of the liver and his father was observed to have haemochromatosis-type arthropathy. Only one previous case of hyperferritinaemia associated with the p.(Ala27Val) mutation has been reported in the literature (Thurlow *et al*, 2012). The individual described did not appear to have any evidence of iron overload.

Both mutations here affect positions in the 'alpha' helix near the N terminus of L-ferritin. It has been hypothesised that by increasing the hydrophobic cluster at the N terminus, hypersecretion of ferritin light chain ensues (Kannengiesser *et al*, 2009). It is not clear how iron overload might occur in this context, however, we observed a potential phenotype with the p.(Ala27Val) mutation. Of note, *in silico* analysis predicts a greater impact on protein function for p.(Ala27Val) compared with p.(Thr30Ile).

In summary, we have characterised a UK cohort of patients with isolated hyperferritinaemia due to mutations in exon 1 of the *FTL* gene. We speculate there is a degree of genotype-phenotype correlation within this limited pool of known *FTL* variants, p.(Ala27Val) possibly leading to iron loading whereas p.(Thr30Ile) would seem entirely benign. Only limited published data of 'hereditary hyperferritinaemia without cataracts' exist to date. It is important that clinicians are aware of this relatively novel syndrome when investigating patients with hyperferritinaemia and to incorporate *FTL* gene sequencing in their clinical algorithms (Cullis *et al*, 2018). Patients may be spared superfluous testing, delay in diagnosis

and unnecessary venesection. Increased awareness of *FTL* gene testing should lead to ready diagnosis and expand our understanding of this hitherto poorly described disorder.

Acknowledgements

Meha Bhuvu, Sambit Sen and William Griffiths wrote the paper as well as providing clinical data.

Patricia Bignell provided critical analysis of the paper as well as clinical data.

Terry Elsey and Helen Dreau provided sequencing data.

Wale Atoyebi, Charlotte Bradbury and Rosalynd Johnston provided clinical data.

References

Beaumont, C., Leneuve, P., Devaux, I., Scoazec, J., Berthier, M., Loiseau, M., Grandchamp, B. and Bonneau, D. (1995) Mutation in the iron responsive element of the L ferritin mRNA in a family with dominant hyperferritinaemia and cataract. *Nature Genetics*, **11**, 444-446.

Cullis, J.O., Fitzsimons, E., Griffiths, W.J.H., Tsochatzis, E. and Wayne, D. (2018) Investigation and management of a raised serum ferritin. *British Journal of Haematology*, *in press*.

Millonig, G., Muckenthaler, M. U. and Mueller, S. (2010) Hyperferritinaemia-cataract syndrome: Worldwide mutations and phenotype of an increasingly diagnosed genetic disorder. *Human Genomics*, **4**, 250.

Kannengiesser, C., Jouanolle, A., Hetet, G., Mosser, A., Muzeau, F., Henry, D., Bardou-Jacquet, E., Mornet, M., Brissot, P., Deugnier, Y., Grandchamp, B. and Beaumont, C. (2009) A new missense mutation in the L Ferritin coding sequence associated with elevated levels of glycosylated ferritin in serum and absence of iron overload. *Haematologica*, **94**, 335-339.

Pietrangelo, A. (2004) The ferroportin disease. *Blood Cells, Molecules, and Diseases*, **32**, 131-138.

Thurlow, V., Vadher, B., Bomford, A., DeLord, C., Kannengiesser, C., Beaumont, C. and Grandchamp, B. (2012) Two novel mutations in the L ferritin coding sequence associated with benign hyperferritinaemia unmasked by glycosylated ferritin assay. *Annals of Clinical Biochemistry*, **49**, 302-305.

Worwood, M. (1990) Ferritin. *Blood Reviews*, **4**, 259-269.

Table 1**Characterization of affected cases with *FTL* gene exon 1 mutation**

Patient	Familial cluster	Gender/age	Mutation(s)	Ferritin (mcg/L)	Tf sat	IO signs	MRI IO	Venesected	VIA
1	FTL_1	M/35	FTL: p.Thr30Ile	1795	28%	Nil	No	No	n/a
2	FTL_1	F/60	FTL: p.Thr30Ile	580	24%	Nil	n/a	No	n/a
3	FTL_2	M/66	FTL: p.Thr30Ile	1500	n/a	Nil	No	No	n/a
4	FTL_2	M/59	FTL: p.Thr30Ile	2405	n/a	Nil	No	No	n/a
5	FTL_3	M/40	FTL: p.Thr30Ile	1335	n/a	Nil	No	Yes	Yes
6	FTL_4	F/20	FTL: p.Thr30Ile	780	36%	Nil	No	No	n/a
7	FTL_5	M/28	FTL: p.Thr30Ile	1384	44%	Nil	No	Yes	No
8	FTL_6	M/68	FTL: Ala27Val	4500	11%	Arthropathy	n/a	Yes	Yes
9	FTL_6	M/38	FTL: Ala27Val	2060	47%	Nil	Yes	Yes	No
10	FTL_6	F/41	FTL: Ala27Val	2000	46%	Nil	n/a	Yes	No
11	FTL_7	F/61	FTL: p.Thr30Ile	1861	39%	Nil	No	Yes	Yes
12	FTL_7	F/60	FTL: p.Thr30Ile	1095	28%	Nil	No	Yes	Yes
13	FTL_8	F/46	FTL: p.Thr30Ile	800	30%	Nil	n/a	No	n/a
14	FTL_9	M/37	FTL: p.Thr30Ile	980	39%	Nil	n/a	No	n/a
15	FTL_10	F/58	FTL: p.Thr30Ile	789	13%	Nil	n/a	No	n/a
16	FTL_11	M/51	FTL: p.Thr30Ile	2152	24%	Nil	n/a	No	n/a
17	FTL_12	F/67	FTL: p.Thr30Ile HFE:C282Y/H63D	1400	36%	Nil	n/a	Yes	No

Key:

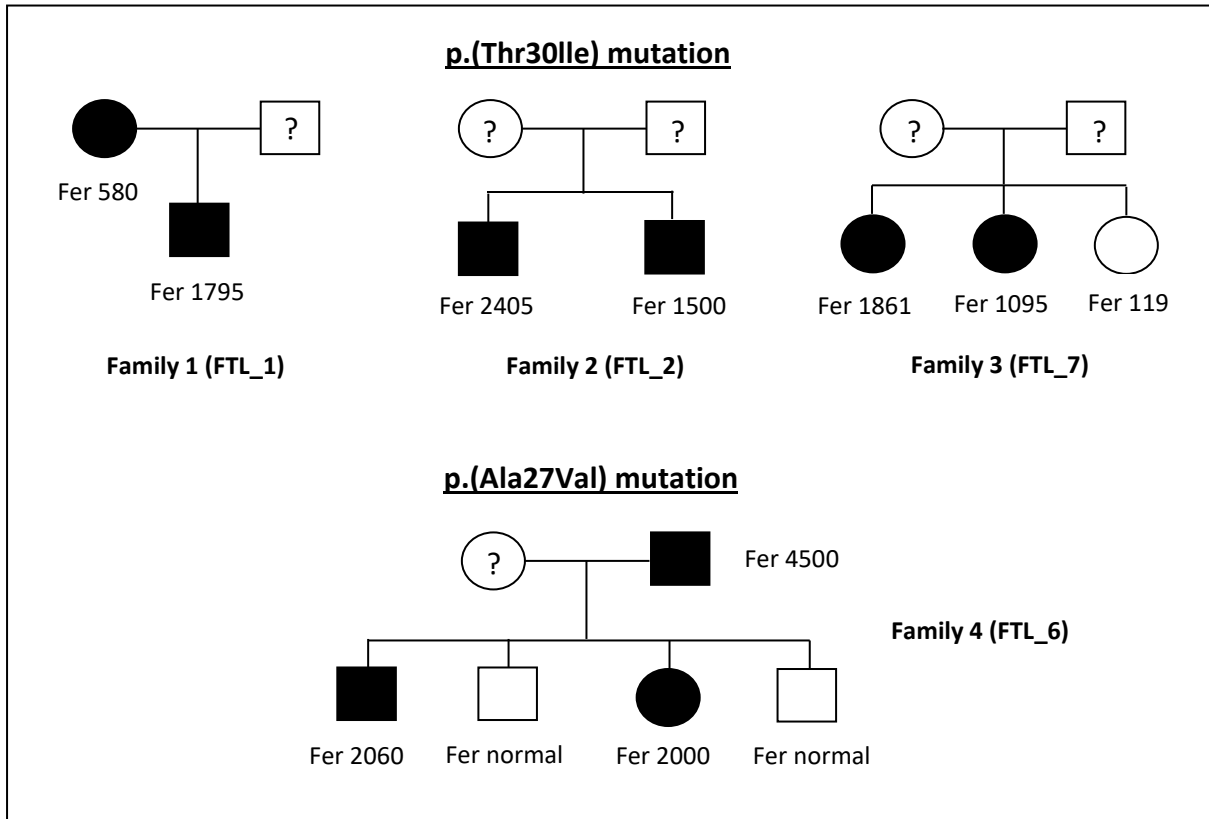
Tf sat = transferrin saturation

IO = iron overload

VIA = venesection induced anaemia

Figure 1

Families characterised with and without *FTL* variants in the study cohort



Key:

□ Male

■ ● Affected

○ Female

□ ○ Not affected

Fer = ferritin