



Abid, M. B., Wadera, K., Bird, J. M., Pawade, J., & Marks, D. I. (2018). Alemtuzumab-based therapy for Secondary Malignant Histiocytosis arising from Pre-B-ALL. *Leukemia Research Reports*, 9, 5-8. <https://doi.org/10.1016/j.lrr.2017.11.003>

Publisher's PDF, also known as Version of record

License (if available):
CC BY-NC-ND

Link to published version (if available):
[10.1016/j.lrr.2017.11.003](https://doi.org/10.1016/j.lrr.2017.11.003)

[Link to publication record on the Bristol Research Portal](#)
PDF-document

This is the final published version of the article (version of record). It first appeared online via Elsevier at <https://www.sciencedirect.com/science/article/pii/S2213048917300250> . Please refer to any applicable terms of use of the publisher.

University of Bristol – Bristol Research Portal

General rights

This document is made available in accordance with publisher policies. Please cite only the published version using the reference above. Full terms of use are available: <http://www.bristol.ac.uk/red/research-policy/pure/user-guides/brp-terms/>



Alemtuzumab-based therapy for Secondary Malignant Histiocytosis arising from Pre-B-ALL

Muhammad Bilal Abid^{a,b,*}, Karan Wadhwa^a, Jenny M. Bird^a, Joya Pawade^c, David I. Marks^a

^a Division of Hematology & Bone Marrow Transplantation, University Hospitals of Bristol NHS Foundation Trust, Bristol, United Kingdom

^b Division of Internal Medicine, Medical College of Wisconsin (MCW), Milwaukee, WI, USA

^c Division of Pathology, University Hospitals of Bristol NHS Foundation Trust, Bristol, United Kingdom

ARTICLE INFO

Keywords:

Secondary Malignant Histiocytosis (SMH)
Pre-B-Cell Acute Lymphoblastic Leukemia (Pre-B-ALL)
Transdifferentiation
C/EBP α
PAX5

Clinical Practice Points:

- Secondary Malignant Histiocytosis (SMH) is an exceedingly rare, life-threatening condition that invariably occurs in the presence of an underlying monoclonal hematologic disorder. Prognosis of SMH remains dismal and there is no established treatment.
- We report a case of a patient who developed SMH during induction chemotherapy for his underlying pre-B-ALL, that caused persistently high fevers and was only diagnosed by a marrow while cytopenic in phase 2 induction. He was treated with alemtuzumab-based therapy that reduced the histiocytic infiltration of the bone marrow from 80% to 15% and made him eligible to undergo T-cell replete allogeneic stem transplantation from his sibling.
- This report is the first to highlight the role of alemtuzumab, an anti-CD52 monoclonal antibody, in clonal disorders originating from transdifferentiation.
- The alemtuzumab-based regimen should be reserved only for carefully selected allogeneic transplant patients.

1. Introduction

Secondary Malignant Histiocytosis (SMH) is a distinct entity and forms part of a spectrum of disorders of the monocyte-phagocytic lineage, categorised into five main groups in the current WHO classification. It includes conditions such as Langerhans Cell Histiocytosis (LCH), Hemophagocytic Lymphohistiocytosis (HLH), Rosai-Dorfman disease, cutaneous and mucocutaneous manifestations of these disorders and primary and secondary malignant histiocytosis [1–3]. It can occur either as a sporadic illness or secondary to clonally-related hematological malignancies. Pathogenesis of SMH remains unclear but it is derived from cells of the Macrophage/Dendritic Cell (DC) system and is most commonly associated with Acute Lymphoblastic Leukemia (ALL) and Follicular Lymphomas, as well as myeloid disorders like Chronic Myelomonocytic Leukemia (CMML) and Acute Myeloid Leukemia (AML). SMH is diagnosed based on anaplastic morphology,

expression of macrophage and DC markers, a definite temporal and a probable clonal relationship with the primary hematologic neoplasm [1]. The marked hyperferritinemia, triglyceridemia and hemophagocytosis in the bone marrow, typical of HLH, are generally not seen in SMH.

2. Case report

A 40-year-old male, with no past medical history of significance other than smoking, attended the general practitioner's clinic with three weeks' history of feeling generally unwell and one-week history of night sweats. At presentation, the patient did not manifest any signs or symptoms of marrow failure. He also did not have pallor, jaundice, lymphadenopathy, or hepatosplenomegaly. Initial full blood count (FBC) showed a hemoglobin of 14.4 g/dL, platelets of $59 \times 10^9/L$, white cell count of $38.8 \times 10^9/L$ and neutrophils of $4.11 \times 10^9/L$.

* Correspondence to: Division of Internal Medicine, Medical College of Wisconsin, 9200 W Wisconsin Ave, Milwaukee, WI 53226, USA.
E-mail addresses: bilal_abid@hotmail.com, mabid@mcw.edu (M.B. Abid).

<https://doi.org/10.1016/j.lrr.2017.11.003>

Received 20 May 2017; Received in revised form 30 September 2017; Accepted 26 November 2017

Available online 05 December 2017

2213-0489/© 2017 The Authors. Published by Elsevier Ltd. This is an open access article under the CC BY-NC-ND license (<http://creativecommons.org/licenses/by-nc-nd/4.0/>).

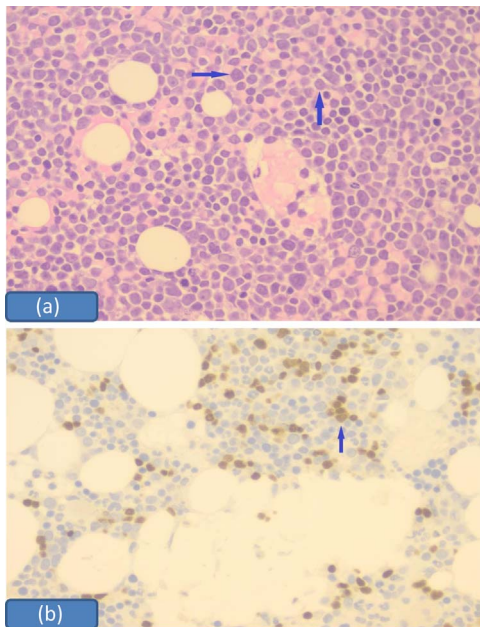


Fig. 1. (a): Bone Marrow Aspirate (H&E X 100) shows the presence of lymphoblasts (arrows), consistent with ALL. (b): Bone Marrow Trepine (H&E X 100) shows the persistence of lymphoblasts, highlighted with TDT staining (arrow), post-induction chemotherapy

Liver function tests, lactate dehydrogenase (LDH), creatinine, electrolytes and coagulation screen were normal. A peripheral blood film revealed lymphoblasts.

Bone marrow aspirate and trephine showed a hypercellular marrow with decreased tri-lineage hematopoiesis and 90% blasts [Fig. 1(a)]. Flow cytometry confirmed Pre-B-Cell Acute Lymphoblastic Leukemia (Pre-B-ALL) and karyotyping met the criteria for complex cytogenetics [4]. Molecular analyses were negative for a bcr-abl1 transcript (both p190 and p210 variants).

The patient was enrolled in the UKALL14 trial (09/H0711/90) in May 2016 and was randomized to receive 4 doses of rituximab in phase-1 induction. Bone marrow assessment after phase-1 of 4-drug induction chemotherapy revealed the persistence of 13% blasts by flow cytometry and 15% on trephine [Fig. 1(b)]. As per protocol, it was decided that he should continue with phase-2 of induction therapy (cyclophosphamide, cytosine arabinoside and 6-mercaptopurine). He then developed persistently high fevers and was treated with broad-spectrum antibiotics for neutropenic fever. Anti-viral and anti-fungal prophylaxis was continued during this time. Microbiological investigations for viral, fungal and bacterial pathogens were repeatedly negative. Imaging studies including a CT and PET scans did not show lymphadenopathy, hepatosplenomegaly, or other organ involvement. In view of his persistent fever, a mid-cycle bone marrow aspirate and trephine were performed which showed a reduction in lymphoblasts to 5% by flow cytometry and an extensive infiltration of malignant histiocytes, amounting to nearly 80%, with no associated hemophagocytosis [Figs. 2(a) & (b); 3(a) & (b)]. This 'secondary malignant histiocytosis' (SMH) was considered to be the cause of his persistent fevers, based on flow cytometric analysis. Karyotyping was not performed on the marrow at this stage. There was mild hepatomegaly, no splenomegaly, ferritin levels were 1197 microgram/L (normal 10–400 mcg/L), whereas LDH and triglyceride levels were normal. Other differential diagnoses which were ruled out included: Anaplastic large cell lymphoma (negative staining for CD30 and ALK1), carcinoma (negative staining for cytokeratin) and dendritic cell neoplasms (negative staining for CD23 and S100 as well as morphology). Phase-2 induction chemotherapy was discontinued.

His secondary malignant histiocytosis was treated with alemtuzumab (Campath) 2.4 mg/kg over 5 days [5], intravenous

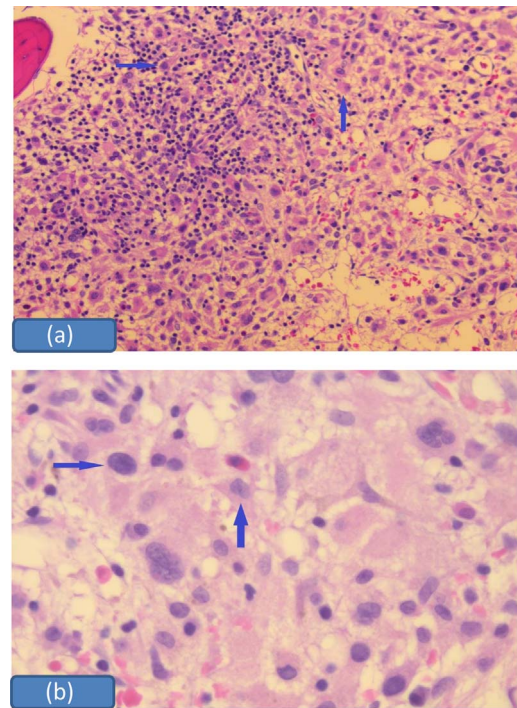


Fig. 2. (a & b): Bone Marrow Trepine shows pleomorphic histiocytes (arrows), consistent with Secondary Malignant Histiocytosis

immunoglobulins (IVIg) 1 gm/kg for 2 days and methylprednisolone 2 mg/kg for 5 days. He defervesce after 48 h and became well and ambulant. Assessment of bone marrow on day 15, 2 weeks after receiving alemtuzumab, showed a decrease in histiocytes to less than 15% and lymphoblasts to 0.1% by flow cytometry.

With an excellent performance status, normalization of blood counts and a partial response of his SMH, it was decided to proceed to T-cell replete allogeneic stem transplantation from his sibling with fludarabine (40 mg/m²/day) on days – 7 to – 3 and IV busulfan (130 mg/m²/day) conditioning on days – 6 to – 3 [6]. His bone marrow examination, 70 days' post-allogeneic stem cell transplantation, showed a complete morphological [Fig. 4], flow cytometric and cytogenetic remission. He developed features of mild skin graft versus host disease (GVHD), 2 months' post-transplant, which was treated with topical steroids. The patient maintained complete remission for 8 months' post-allogeneic stem cell transplant but has relapsed with ALL in thigh muscles, the middle ear and the leptomeninges. Biopsies from two sites reveal no evidence of SMH.

3. Discussion

Histiocytoses encompass a rare, heterogeneous group of disorders characterized by the aggregation of cells of mononuclear-phagocytic lineage and occur more commonly in children. Histiocytes, a morphological term for tissue-dweller macrophages, perform the phagocytic function whereas dendritic cells (DC) are involved in antigen presentation and T-cell activation. Nomenclature for this rare entity has evolved since 1987 and most recent classification group > 100 subtypes into 5 categories [1,2].

Secondary Malignant Histiocytosis (SMH) is a neoplastic disorder occurring simultaneously or after another hematologic malignancy and is classified under "M group (MH: Malignant Histiocytoses)" according to the revised classification of histiocytic disorders. SMH is diagnosed based on anaplastic morphology, expression of macrophage and DC markers, a definite temporal and a probable clonal relationship with the primary hematologic neoplasm [2,3].

Differential diagnosis mainly includes high-grade lymphoma,

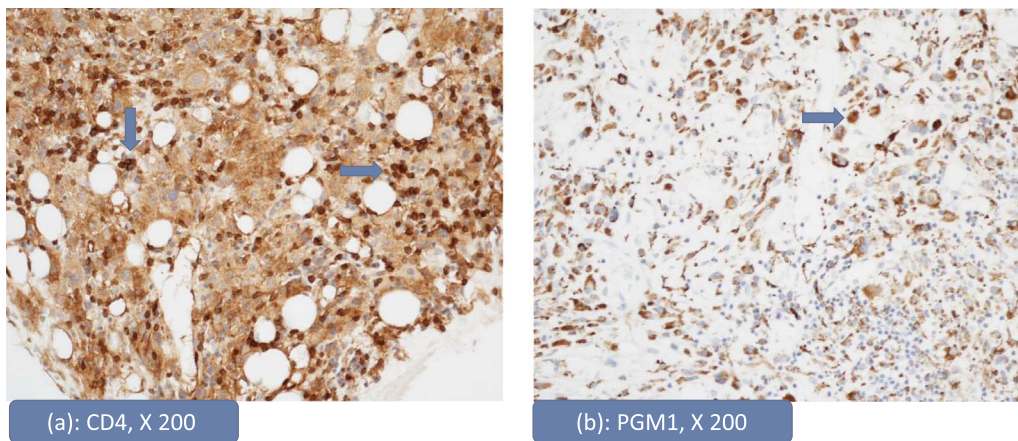


Fig. 3. (a & b): Bone Marrow shows histiocytosis on immunohistochemistry (IHC): Bone Marrow Trephine shows immunostaining for CD4 (X200) [a] and PGM1 (X200) [b], indicative of histiocytic infiltration.

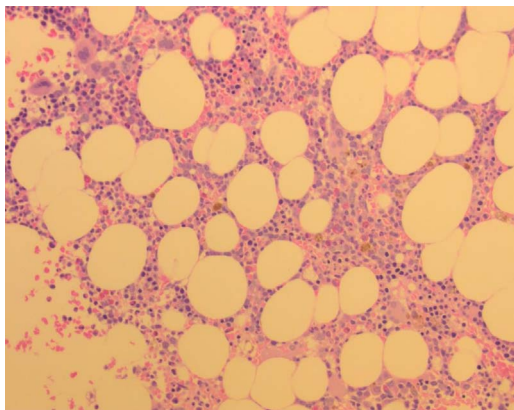


Fig. 4. Bone Marrow Trephine, post-allogeneic transplantation, shows trilineage hematopoiesis with the absence of lymphoblasts and histiocytes.

metastatic carcinoma, malignant melanoma, primary malignant histiocytosis and requires the establishment of anaplastic morphology and staining markers of macrophages/DCs, without synchronous hematological malignancy, via negative staining pattern and hence the exclusion of other tumors.

SMH evolves through transdifferentiation, a series of processes where one differentiated somatic cell line transforms into another, without going through a pluripotent cell phase [7]. Recent studies have highlighted the important role transcription factors play in the transdifferentiation of somatic and malignant cell lines, to specialized and pluripotent stem cells, as well as across different hematopoietic lineages. Transcription factor C/EBP α , in particular, appears to play an important role in relation to the pre-B cell to macrophage transdifferentiation [8,9].

We report a case of SMH developing synchronously with pre-B ALL in a 40-year-old male. There is no standard of care treatment for SMH currently and prognosis remains poor, especially in patients with multisystem involvement. Data regarding treatment is derived from other related histiocytic disorders, commonly HLH, and includes etoposide-based combination chemotherapy [1–3]. There are reports in the literature of the use of Alemtuzumab in LCH and HLH [5,10] but seldom for its use in the treatment regimens for SMH, likely because of the rarity of SMH itself. Albeit malignant histiocytes were not examined for CD52 expression in this case, evidence from response of other biologically and clinically similar conditions to alemtuzumab was extrapolated and led to the clinical decision of utilizing this monoclonal antibody in the setting of SMH and this patient responded well to alemtuzumab, intravenous immunoglobulin and methylprednisolone.

4. Conclusion

This report is the first to highlight the role of alemtuzumab, an anti-CD52 monoclonal antibody, in clonal disorders originating from transdifferentiation. However, the alemtuzumab-based regimen should be reserved only for carefully selected allogeneic transplant patients, given its considerably long lympholytic half-life and established roles in T-cell depletion and GVHD. Further studies are needed to better understand the transdifferentiation phenomenon involved in SMH so that specific molecular targets can be identified in order to improve the dismal outlook associated with SMH.

Informed consent

Informed consent was obtained from the patient prior to publication.

Disclosure

The authors declare no conflict of interest.

Authors contributions

MBA conceived of the study and wrote the manuscript. JP and KW helped in the preparation of the manuscript. JP provided the histopathology images. JMB and DIM rendered patient care and performed a critical review of the manuscript. All authors read and approved the final manuscript.

References

- [1] K. Lehmsberg, K.E. Nichols, J.I. Henter, et al., Consensus recommendations for the diagnosis and management of hemophagocytic lymphohistiocytosis associated with malignancies, *Haematologica* 100 (8) (2015) 997–1004.
- [2] J.F. Emile, O. Abla, S. Fraitag, et al., Revised classification of histiocytoses and neoplasms of the macrophage-dendritic cell lineages, *Blood* 127 (22) (2016) 2672–2681.
- [3] J.I. Henter, A. Horne, M. Aricó, et al., HLH-2004: Diagnostic and therapeutic guidelines for hemophagocytic lymphohistiocytosis, *Pediatr. Blood Cancer* 48 (2) (2007) 124–131.
- [4] A.V. Moorman, C.J. Harrison, G.A. Buck, et al., Karyotype is an independent prognostic factor in adult acute lymphoblastic leukemia (ALL): analysis of cytogenetic data from patients treated on the Medical Research Council (MRC) UKALLXII/Eastern Cooperative Oncology Group (ECOG) 2993 trial, *Blood* 109 (8) (2007) 3189–3197.
- [5] R.A. Marsh, C.E. Allen, K.L. McClain, et al., Salvage therapy of refractory hemophagocytic lymphohistiocytosis with alemtuzumab, *Pediatr. Blood Cancer* 60 (1) (2013) 101–109.
- [6] G. Kunter, J.B. Perkins, J. Pidala, et al., Pharmacokinetically-targeted BU and fludarabine as conditioning before allogeneic hematopoietic cell transplantation for adults with ALL in first remission, *Bone Marrow Transplant.* 49 (2014) 11–16.
- [7] T. Graf, T. Enver, Forcing cells to change lineages, *Nature* 462 (7273) (2009) 587–594.

- [8] C.V. Oevelen, S. Collombet, G. Vicent, et al., C/EBP α activates pre-existing and de novo macrophage enhancers during induced Pre-B Cell transdifferentiation and myelopoiesis, *Stem Cell Rep.* 5 (2) (2015) 232–247.
- [9] F. Rapino, E.F. Robles, J.A. Richter-Larrea, E.M. Kallin, J.A. Martinez-Climent, T. Graf, C/EBP α induces highly efficient macrophage transdifferentiation of B lymphoma and leukemia cell lines and impairs their tumorigenicity, *Cell Rep.* 3 (4) (2013) 1153–1163.
- [10] M.B. Jordan, K.L. McClain, X. Yan, J. Hicks, R. Jaffe, Anti-CD52 antibody, alemtuzumab, binds to Langerhans cells in Langerhans cell histiocytosis, *Pediatr. Blood Cancer* 44 (3) (2005) 251–254.