



Walter, C., Dietrich, T., Ower, P., Tank, M., West, N., Needleman, I. G., Hughes, F. J., Wadia, R., Milward, M., Hodge, P., & Chapple, I. (2019). Periodontal diagnosis in the context of the BSP implementation plan for the 2017 classification system of periodontal diseases and conditions: Presentation of a pair of young siblings with periodontitis. *British Dental Journal*, 226(1), 23-26.
<https://doi.org/10.1038/sj.bdj.2019.2>

Peer reviewed version

Link to published version (if available):
[10.1038/sj.bdj.2019.2](https://doi.org/10.1038/sj.bdj.2019.2)

[Link to publication record in Explore Bristol Research](#)
PDF-document

This is the author accepted manuscript (AAM). The final published version (version of record) is available online via Springer Nature at <https://doi.org/10.1038/sj.bdj.2019.2> . Please refer to any applicable terms of use of the publisher.

University of Bristol - Explore Bristol Research

General rights

This document is made available in accordance with publisher policies. Please cite only the published version using the reference above. Full terms of use are available:
<http://www.bristol.ac.uk/red/research-policy/pure/user-guides/ebr-terms/>

**Periodontal diagnosis in the context of the BSP implementation plan for the
2017 classification system of periodontal diseases and conditions:**

Presentation of a pair of young siblings with periodontitis

Clemens Walter*, Thomas Dietrich, Ower P, Tank M, West NX, Needleman I,
Hughes FJ, Wadia R, Milward MR, Hodge PJ, Chapple ILC, on behalf of the British
Society for Periodontology

***Corresponding author:**

Prof. Dr. Clemens Walter

University Center for Dental Medicine (UZB)

Department of Periodontology, Endodontology and Cariology

Hebelstrasse 3, 4056 Basel (Switzerland)

Tel.: +41-61-2672628

Fax: +41-61-2672659

Email: clemens.walter@unibas.ch

In brief

This case report illustrates the application of the BSP implementation plan for diagnosing periodontitis patients according to the 2017 classification. It highlights the potential for aggregation of periodontitis in families and suggests that relatives of young patients with severe periodontitis are also examined.

Abstract

Introduction: The objective of this case report is to illustrate the diagnosis and classification of periodontitis according to the 2017 Classification system as recommended in the British Society of Periodontology (BSP) implementation plan.

Case report: We describe two cases in the form of a pair of siblings, who developed periodontitis very early in life. A 19-year-old female was diagnosed with “*Generalised periodontitis; Stage III/Grade C; currently unstable*”. Her 14-year-old sister was diagnosed with “*Localised periodontitis; Stage II, Grade C; currently unstable*”.

Conclusion: The present case report presents an example for the application of the new classification system and illustrates the importance of a periodontal check for children and adolescents and/or their relatives.

Keywords: hereditary, stage, grade, aggressive periodontitis, BSP implementation, 2017 classification.

Introduction

The aetiology and pathogenesis of periodontitis in adolescents and young adults has been the subject of much debate in recent decades^{1, 2, 3}. Formerly known as 'early onset periodontitis', 'rapidly progressive periodontitis', 'localised juvenile periodontitis' or 'generalised juvenile periodontitis', these disease forms were collectively re-named as 'aggressive periodontitis' in the 1999 classification system³. However, clear evidence that the aetiology or pathogenesis of periodontitis in adolescents or young adults is fundamentally different from that occurring in older adults is lacking.

Therefore, the 2017 classification does not distinguish different types of periodontitis based on age at diagnosis or rate of disease progression⁴. Rather, the introduction of a staging and grading system provides for an explicit distinction of the presenting severity/extent (stage) and disease susceptibility/progression (grade)⁵, in the absence of therapeutic intervention.

In this case presentation we report on a pair of siblings with periodontitis formerly classified as localised and generalised aggressive periodontitis. We demonstrate step-by-step how the BSP recommendations for implementation of the 2017 classification system can be applied in practice to reach an appropriate periodontal diagnosis⁶.

Case Reports

Case 1

A 19-year-old female presented in good general health. The patient was a never-smoker. Intraoral clinical inspection revealed moderate levels of oral hygiene and signs of gingival inflammation, i.e., redness, and oedema (Figure 1). The patient did not present with overt interproximal recession or clinical attachment loss.

As part of the initial patient assessment a BPE screening examination was indicated (Table 1). The BPE codes of 4 in all sextants were, in the absence of pseudopockets, consistent with a provisional diagnosis of periodontitis and triggered a full periodontal assessment including a 6 point pocket chart, bleeding on probing measures and appropriate radiographs. The full periodontal chart demonstrated deep pockets up to 8mm in all sextants, and all molars exhibited furcation involvement (grade II furcations in all maxillary molars and LR6) (Figure 2). In addition, there were several pockets ≥ 4 mm that bled on probing, indicating unstable periodontitis. The periapical radiographs show evidence of significant bone loss due to periodontitis on all teeth, with the possible exception of UL34 and LR45 (Figure 3).

Hence, given the history (i.e., lack of systemic disease explaining loss of periodontal tissues, e.g. Papillon-Lefevre-Syndrome) and the clinical and radiological findings (interproximal attachment loss/alveolar bone loss due to periodontitis, no papillary necrosis consistent with necrotising periodontal disease), a diagnosis of periodontitis was made.

For every patient diagnosed with periodontitis, staging and grading should be performed as the next step^{4,6}. Bone loss reached into the middle third of the root in many teeth, but did not extend into the apical third on any tooth. Hence, the patient is a patient with stage III periodontitis. Maximum bone loss of approximately 60% is

seen at UR456. As the patient is 19 years of age, the numerical value of the highest percent bone loss exceeds the numerical value of her age (% bone loss/age ratio > 1), which results in an assignment of grade C. At least 24 out of 28 teeth (>30%) are affected by bone loss due to periodontitis, resulting in an extent classification of 'generalised' periodontitis.

Therefore, the definitive diagnosis according to the 2017 classification is:

Generalised periodontitis; Stage III/Grade C; currently unstable.

The diagnostic statement embeds risk factor analysis also and would thus be:

Generalised periodontitis; Stage III/Grade C; currently unstable; RF's = genetic predisposition.

Systematic periodontal treatment needed to be initiated. Note that the outcome of treatment will not result in a change of the initial disease classification as generalised periodontitis; stage III/grade C. This patient will always be a periodontitis patient, with evidence of high disease susceptibility (as indicated by grade C), requiring careful and intensive periodontal maintenance, risk factor control and monitoring.

Following a diagnosis of stage III/grade C periodontitis in this young patient, the patient should be questioned about any siblings. She stated that she had a 14 year old sister, who was invited to attend for an examination.

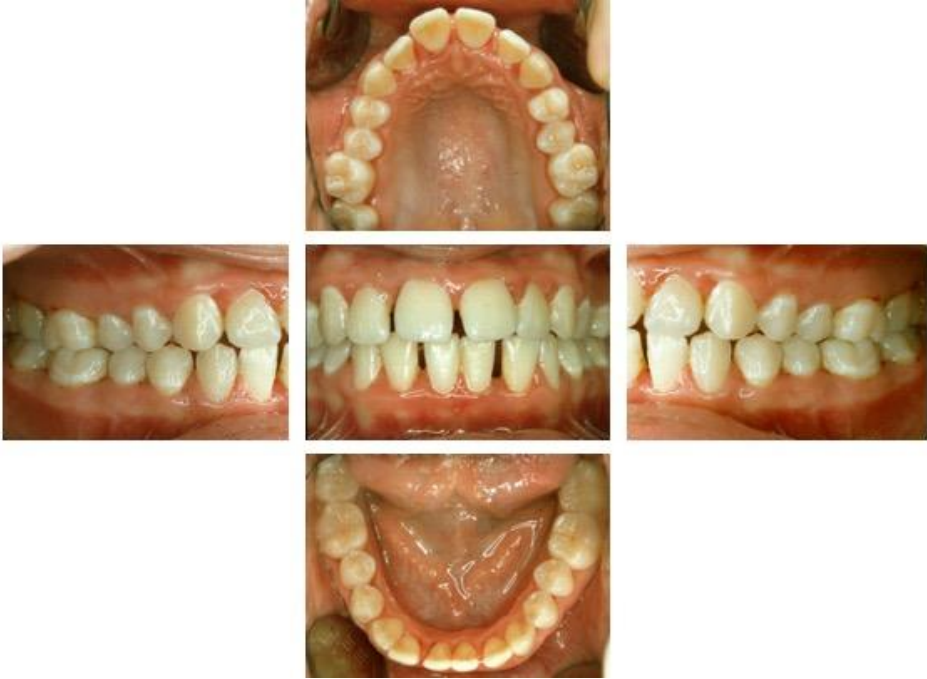

Figure 1: Case 1 - Initial intraoral view of the older sister

4*	4	4*
4*	4	4*

Table 1: Case 1 - BPE examination

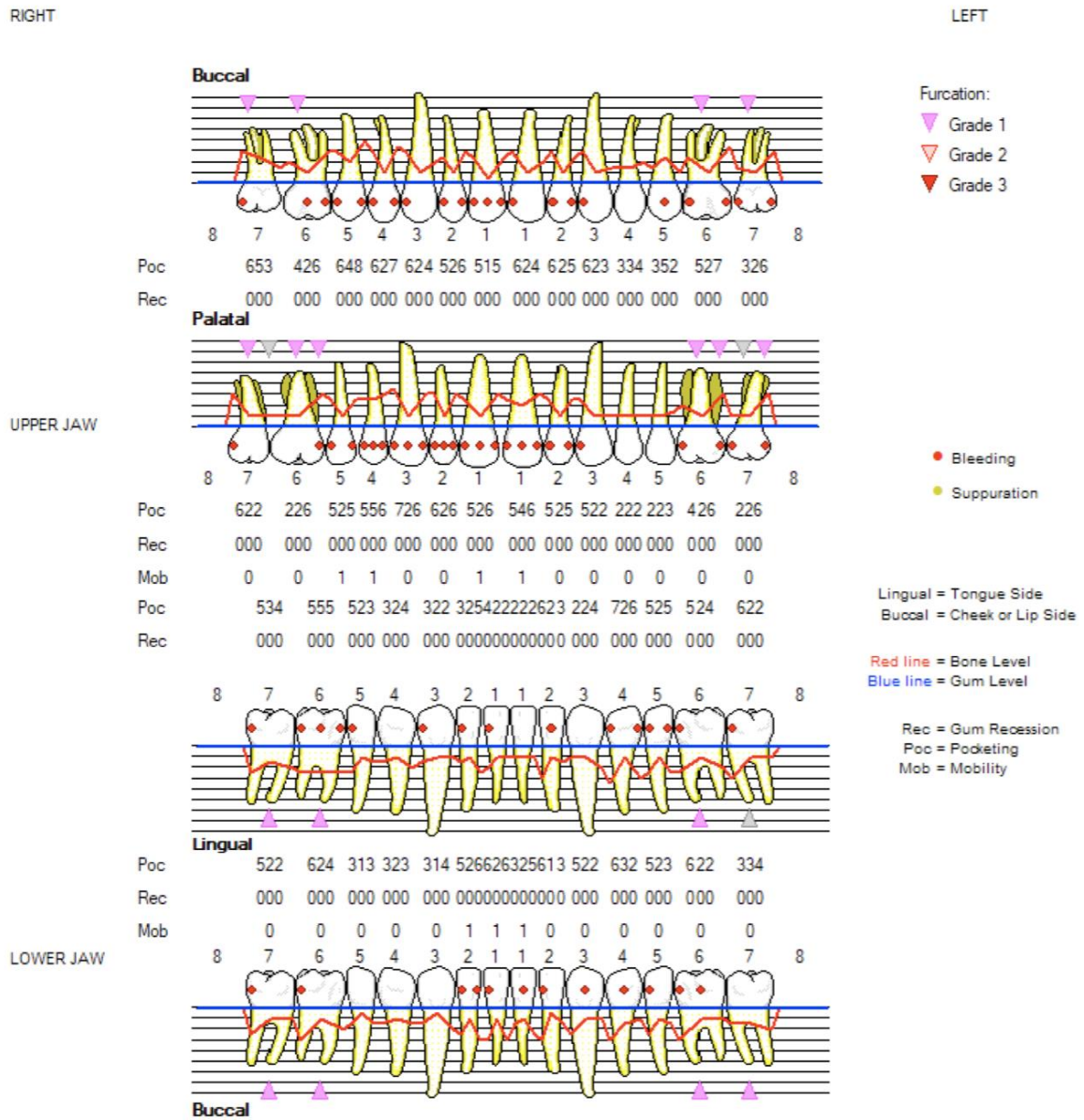


Figure 2: Case 1 - Detailed Periodontal Chart (DPC)

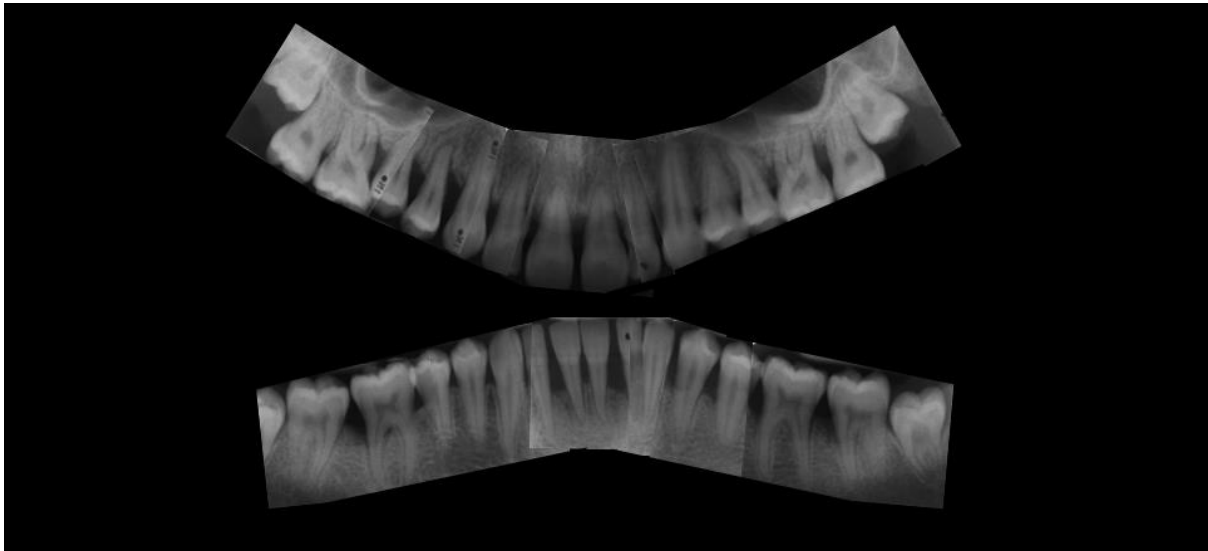


Figure 3: Case 1 - Periapical intraoral radiographs.

Case 2

The 14-year-old female patient was a never-smoker and in good general health. She had not experienced periodontal therapy. An intraoral examination revealed moderate levels of oral hygiene and some signs of minor gingival inflammation (Figure 4). There was no overt interproximal recession or clinical attachment loss. A periodontal screening examination (BPE) was indicated and performed. The BPE revealed codes of 4 in 3 sextants, which were, in the absence of pseudopockets, consistent with a provisional diagnosis of periodontitis and triggered a full periodontal assessment including a 6 point pocket chart with bleeding on probing and appropriate radiographs. The periodontal charting revealed a maximum PPD of 7mm buccally on the UR4 and disto-lingually LR6 and mesio-lingually LR7. Furthermore, UR7, UR6 and LL2 had PPDs of 6mm and PPDs of 4mm and 5mm were evident which bled on probing on UR3, LL1, LR1 and LR2.

A panoramic radiograph and selective periapical radiographs demonstrated bone loss UR456, LR67 and LL2, LL1 and LR1. The medical history and results of the clinical and radiological examination therefore led to a diagnosis of periodontitis. There was evidence of bone loss exceeding 15% of the root length, but not extending into the middle third of the root length (Stage II periodontitis). The maximum bone loss is estimated as 20% (UR456, LL21, LR1). As the patient is 14 years old, the numerical value of her maximum amount of bone loss in percent terms is greater than her age in years ($20 > 14$). Therefore, this case would be classified as Grade C periodontitis. Bone loss due to periodontitis was evident on 8 out of 28 teeth (<30%), resulting in an extent classification of 'localised' periodontitis. Finally, as this was a patient with untreated periodontitis and there was bleeding on probing at sites with pockets equal to and over 4mm, it is classed as 'currently unstable'.

Hence, the final diagnosis was:

Localised periodontitis; Stage II, Grade C; currently unstable.

The diagnostic statement is:

Localised periodontitis; Stage II, Grade C; currently unstable; RF's = genetic predisposition.

A systematic periodontal treatment was initiated.

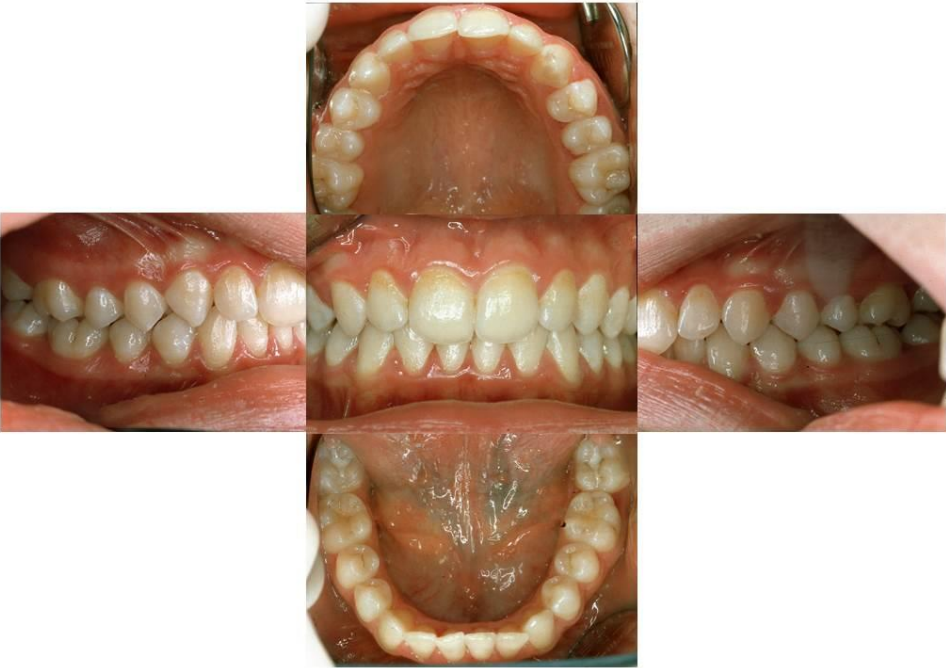

Figure 4: Case 2 - Initial intraoral view of the younger sister

4	3	1
4	4	1

Table 2: Case 2 - BPE examination

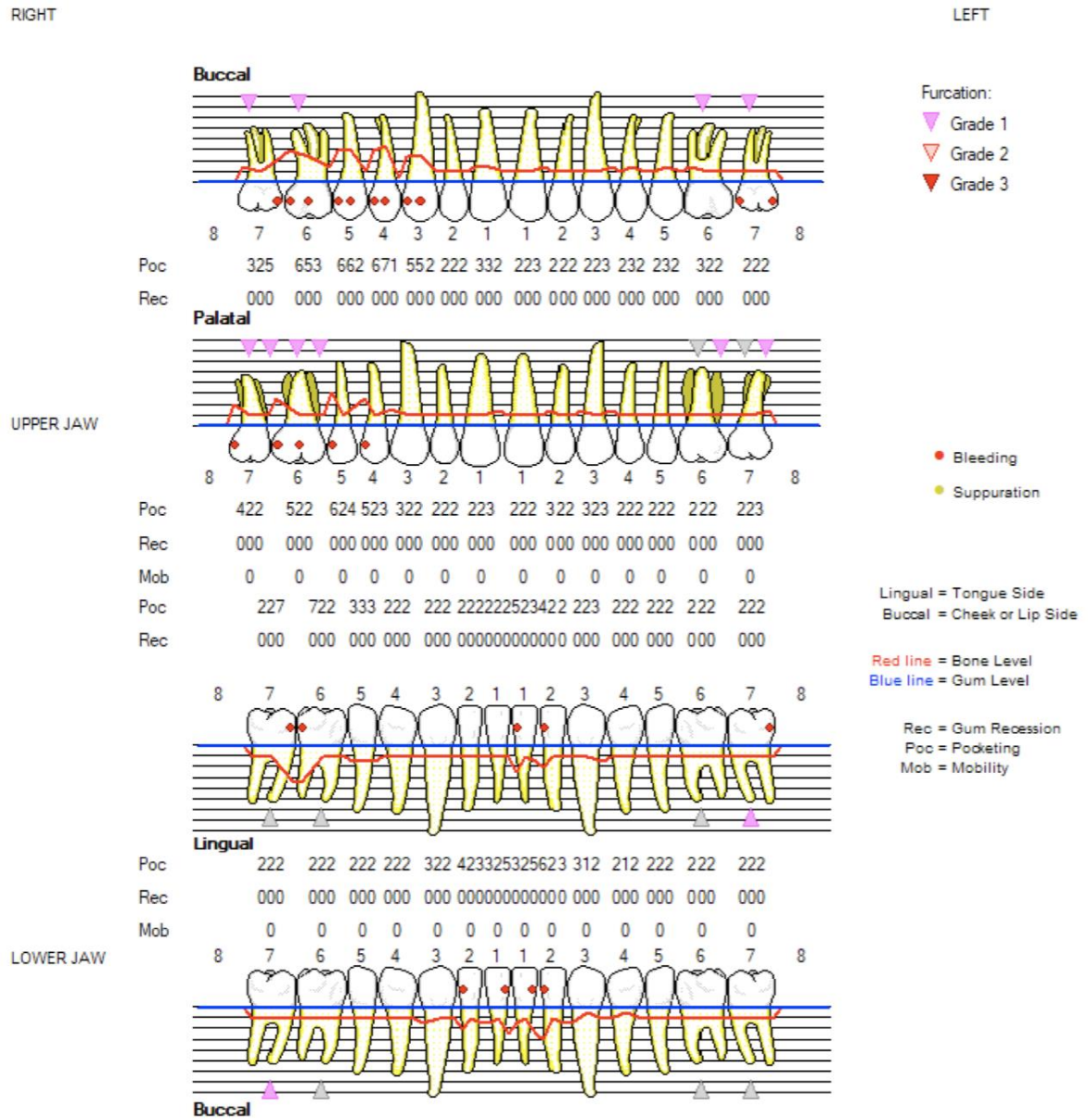


Figure 5: Case 2 - Detailed Periodontal Chart

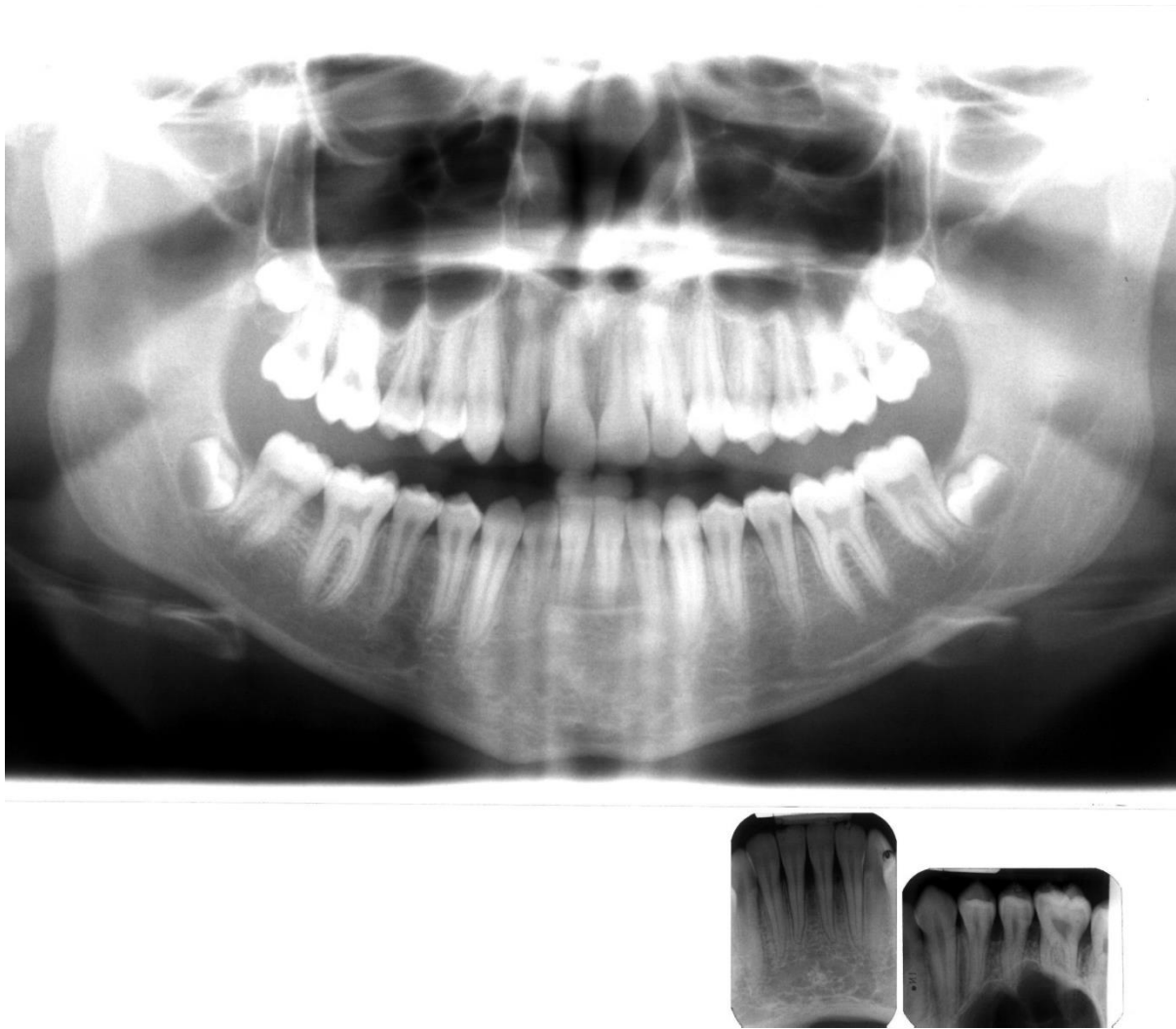


Figure 6: Case 2 - Panoramic radiograph and selective periapical radiographs

Discussion/Summary

This case report provides an example of how to diagnose a pair of siblings according to the 2017 classification of periodontal and peri-implant diseases by following the BSP implementation plan⁶. In the new system, these two young patients are diagnosed as patients with periodontitis. The 19-year-old older sister, who would have been diagnosed with generalised aggressive periodontitis under the 1999 classification, was diagnosed with “Generalised periodontitis; Stage III/Grade C; currently unstable”. Her 14-year-old sister, who would have been diagnosed with

localised aggressive periodontitis under 1999 classification, was diagnosed with “Localised periodontitis; Stage II, Grade C; currently unstable”. The grade C assignment to both patients indicates high disease susceptibility and the need for careful and intensive treatment and maintenance; however, the distinction between stage II and stage III disease appropriately differentiates between the different levels of tissue destruction that has already occurred, which is relevant for the management of these patients. This paper is not aimed at discussing treatment, but decisions on the use of systemic antibiotics as an adjunct in the management of grade C cases, must be taken on a case-by-case basis, accounting for levels of oral hygiene and local risk factors.

References

1. Meyer J, Lallam-Laroye C, Dridi M. Aggressive periodontitis - what exactly is it? *J Clin Periodontol*. 2004 Jul;31(7):586-7.
2. Lang NP, Bartold PM, Cullinam M, Jeffcoat M, Mombelli A, Murakami S, Page RC, Papapanou P, Tonetti MS, Van Dyke TE (1999) International Classification Workshop. Consensus report: Aggressive periodontitis. *Ann Periodontol* 4:53
3. Armitage GC (1999) Development of a classification system for periodontal diseases and conditions. *Ann Periodontol* 4:1-6
4. Papapanou PN, Sanz M, Buduneli N, et al. Periodontitis: Consensus report of workgroup 2 of the 2017 World Workshop on the Classification of Periodontal

and Peri-Implant Diseases and Conditions. *J Clin Periodontol* 2018;45 Suppl 20:S162-S70. doi: 10.1111/jcpe.12946 [published Online First: 2018/06/22]

5. Tonetti MS, Greenwell H, Kornman KS. Staging and grading of periodontitis: Framework and proposal of a new classification and case definition. *J Clin Periodontol* 2018;45 Suppl 20:S149-S61. doi: 10.1111/jcpe.12945 [published Online First: 2018/06/22]

6. **Periodontal diagnosis in the context of the 2017 classification system of periodontal diseases and conditions – Implementation in Clinical Practice:** Dietrich T, Ower P, Tank M, West N, Walter C, Needleman I, Hughes FJ, Wadia R, Milward, MR, Hodge P, Chapple ILC, on behalf of the British Society for Periodontology **XX, XX**