



Wadia, R., Walter, C., Chapple, I., Ower, P., Tank, M., West, N., Needleman, I. G., Hughes, F. J., Milward, M., Hodge, P., & Dietrich, T. (2019). Periodontal diagnosis in the context of the 2017 classification system of periodontal diseases and conditions: Presentation of a patient with periodontitis localised to the molar teeth. *British Dental Journal*, 226(3), 180-182. <https://doi.org/10.1038/sj.bdj.2019.93>

Peer reviewed version

Link to published version (if available):
[10.1038/sj.bdj.2019.93](https://doi.org/10.1038/sj.bdj.2019.93)

[Link to publication record in Explore Bristol Research](#)
PDF-document

This is the author accepted manuscript (AAM). The final published version (version of record) is available online via Nature at <https://doi.org/10.1038/sj.bdj.2019.93> . Please refer to any applicable terms of use of the publisher.

University of Bristol - Explore Bristol Research

General rights

This document is made available in accordance with publisher policies. Please cite only the published version using the reference above. Full terms of use are available:
<http://www.bristol.ac.uk/red/research-policy/pure/user-guides/ebr-terms/>

Periodontal diagnosis in the context of the 2017 classification system of periodontal diseases and conditions: Presentation of a patient with periodontitis localised to the molar teeth.

Wadia R, Walter C, Chapple ILC, Ower P, Tank M, West NX, Needleman I, Hughes FJ, Milward MR, Hodge PJ, Dietrich T

***Corresponding author:**

Professor Thomas Dietrich

Dept of Oral Surgery

The School of Dentistry

University of Birmingham

5 Mill Pool Way

Birmingham

B5 7EG

UK

Email: t.dietrich@bham.ac.uk

In brief

This case report is the third in a series presented in conjunction with the BSP guidance on the implementation of the 2017 classification of periodontal diseases within the United Kingdom. We present a case that would have previously been classified using the 1999 classification system as localised aggressive periodontitis and discuss designation, using the new classification system, as localised periodontitis molar-incisor pattern.

Abstract

The objective of this case report is to illustrate the diagnosis and classification of periodontitis according to the 2017 Classification system as recommended in the British Society of Periodontology (BSP) implementation plan.

A 37-year-old female was diagnosed with periodontitis (Molar-Incisor-Pattern), stage III grade C - currently unstable. Several issues pertinent to the diagnosis of localised forms of periodontitis in young patients are discussed in relation to the current and previous classification systems.

Periodontitis can be limited to a few sites and this case highlights the importance of a careful application of the Basic Periodontal Examination (BPE).

Introduction

The 2017 classification of periodontal diseases and conditions no longer distinguishes different types of periodontitis based on age of disease onset or rate of progression¹⁻³. However, in addition to staging and grading of periodontitis, which captures the severity of periodontitis and the patient's past disease susceptibility/rate of progression, the system requires the description of disease extent. In addition to generalised ($\geq 30\%$ of teeth with attachment loss or bone loss due to periodontitis) and localised ($< 30\%$ of teeth) periodontitis, the new 2017 classification recognises molar-incisor-pattern (MIP) as a distinct pattern³.

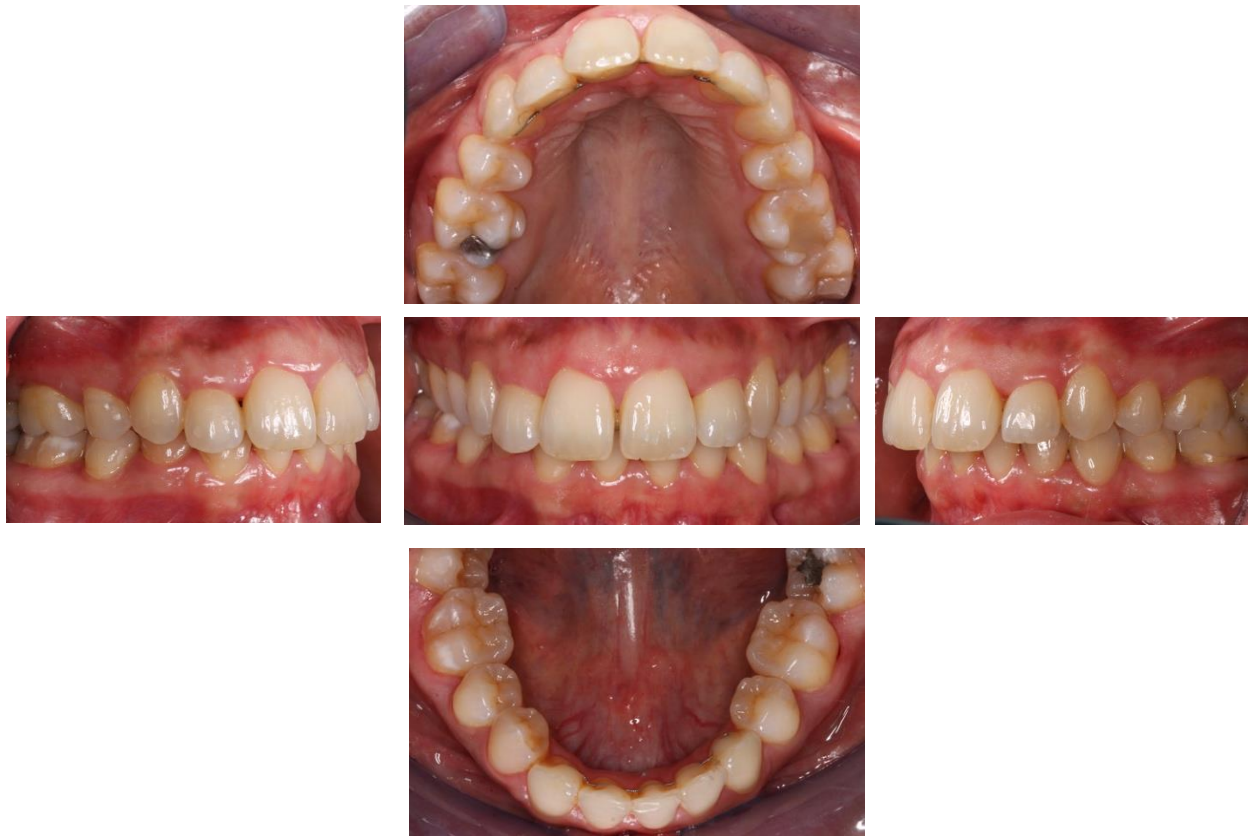
In this case presentation we report on a patient with periodontitis formerly (using the 1999 classification system) classified as localised aggressive periodontitis. We demonstrate step-by-step how the BSP recommendations for implementation of the 2017 classification system can be applied in practice to reach an appropriate periodontal diagnosis.

Case report

A 37-year-old female patient presented complaining of bleeding from her gums when brushing and when biting into hard foods. There was a 12-month history of her symptoms, which initially occurred every few days, but which had become progressively more frequent in recent months; the bleeding was now evident daily. The patient was medically in good health, was a never smoker and reported relatively low stress levels. There was a family history of periodontitis.

Intraoral clinical examination revealed localised marginal gingival inflammation (Figure 1), with a plaque score of 14% and minimal deposits of supra- and sub-gingival calculus. As part of the initial patient assessment, a BPE screening examination was performed (Table 1) as there was no clear and obvious interproximal recession. The BPE included two scores of code 4, providing a provisional diagnosis of periodontitis and triggering a full periodontal assessment including a full-mouth six-point pocket chart, bleeding scores and appropriate radiographs.

Fig. 1 – Clinical Photographs



4	2	3
3	2	4

The detailed periodontal chart revealed localised deep pockets with probing depths ranging from 4-7 mm and with associated bleeding on probing. The UR6 and LL6 had the deepest pockets. Recession was localised and no greater than 1 mm. There was no apparent furcation involvement (Figure 2). The dental panoramic radiograph and supplemental periapical radiographs showed localised bone loss, most significantly affecting the UR6 and LL6, where there were associated vertical bone defects with bone loss of up to 50% (Figure 3).

Fig. 2 – Six point pocket chart

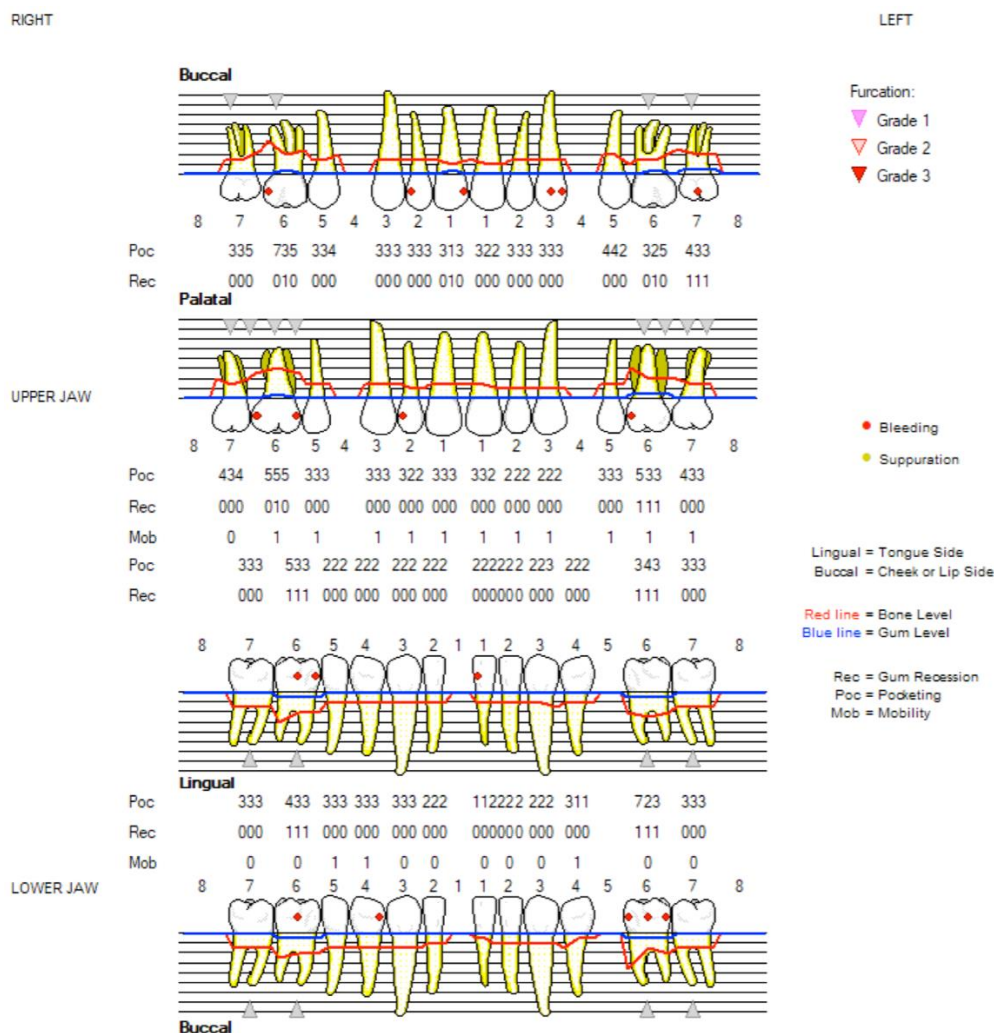
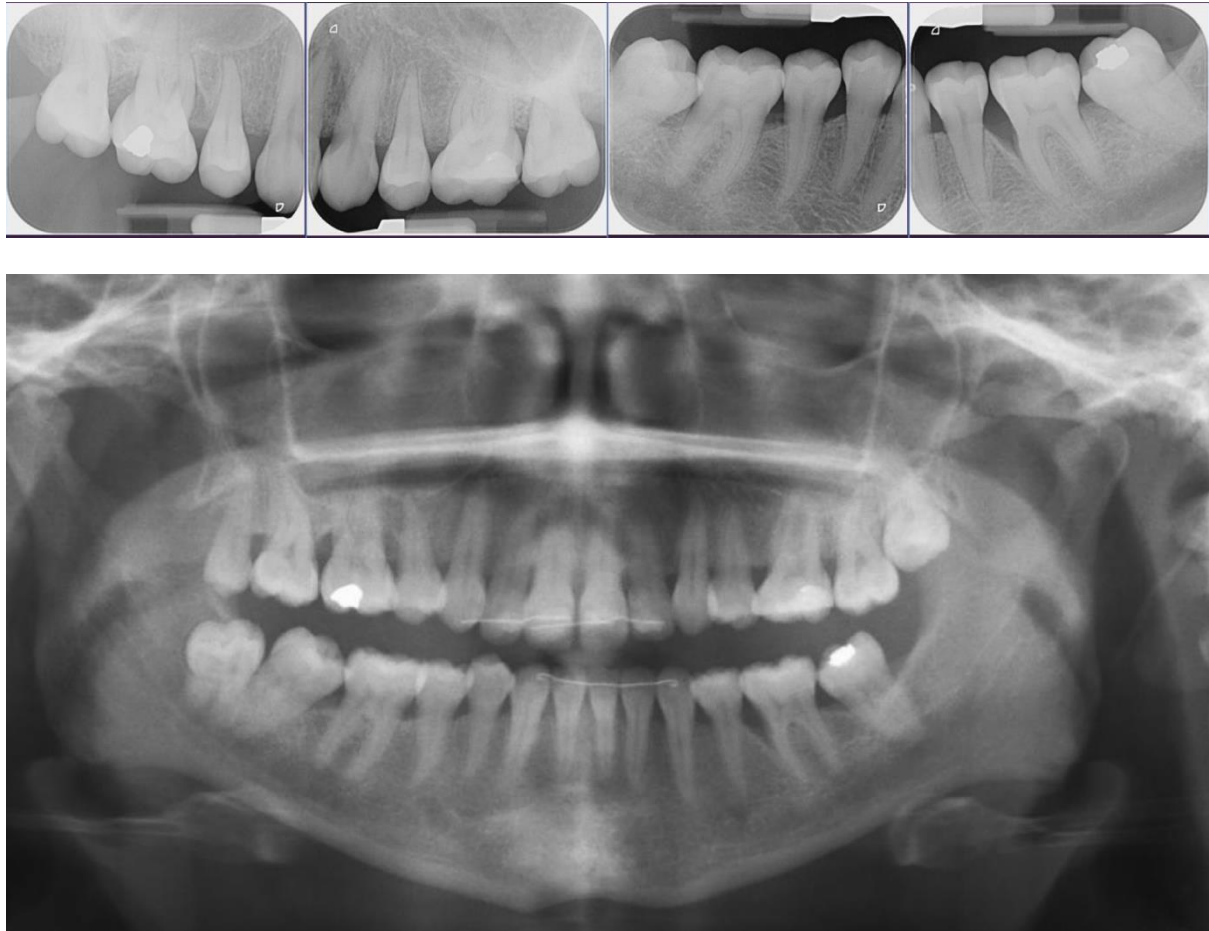

Fig. 3 – Radiographs – DPT & Periapicals



Hence, given the history (i.e., lack of systemic disease explaining loss of periodontal attachment/bone) and the clinical and radiological findings (interproximal attachment loss/alveolar bone loss due to periodontitis, no papillary necrosis consistent with necrotising periodontal disease), a diagnosis of periodontitis was made.

For every patient diagnosed with periodontitis, staging and grading should then be performed to classify the case further¹. When considering the stage of periodontitis, interproximal bone loss at the worst site of bone loss (due to periodontitis) needs to be assessed. Here, the bone loss reaches the mid third of the root but does not extend into the apical third. Therefore, this patient has stage III periodontitis. When

considering the grade, the percentage bone loss is divided by the patient's age. Maximum bone loss of approximately 50% is seen around the UR6 and LL6. As the patient is 37 years of age, the numerical value of the highest percent bone loss exceeds the numerical value of her age (% bone loss/age ratio > 1.0), which results in an assignment of grade C. Less than 30% of teeth are affected by bone loss due to periodontitis, resulting in a "localised" extent. As only molars are affected, the extent can further be described as molar-incisor pattern. When assessing the current periodontal status, as there are periodontal probing depths of more than 4 mm that bleed on probing, this patient is currently unstable. There are no significant lifestyle risk factors for this patient.

Therefore, the definitive diagnosis according to the 2017 classification is:

localised periodontitis (molar-incisor pattern) stage III grade C - currently unstable. This case would have been classified as localised aggressive periodontitis using the previous classification system.

Following treatment and at the reassessment stage, it is important to remember that the outcome of treatment will not change the initial disease classification of localised periodontitis stage III grade C. This patient will always be a periodontitis patient, with evidence of high disease susceptibility (as indicated by grade C), requiring careful and intensive periodontal maintenance. The periodontal status may however change to 'currently stable' or 'currently in remission'.

Discussion/Summary

This case report provides an example of periodontal diagnosis according to the 2017 Classification of Periodontal Diseases and conditions by following the BSP

implementation plan. In the new system, this patient is diagnosed with localised (molar-incisor pattern) stage III grade C periodontitis. According to the 1999 classification, this patient would have been classified as localised aggressive periodontitis. The new 2017 classification system makes explicit the different components that have always formed part of the description of periodontitis, i.e., severity (stage), extent and susceptibility (grade). Specifically, the grade C classification of this patient indicates high disease susceptibility, highlighting the need for careful and intensive periodontal maintenance. The classification as stage III periodontitis indicates that severe loss of periodontal tissues has already occurred; however, the description of the extent as molar-incisor pattern appropriately highlights the specific disease distribution.

The recognition of molar-incisor pattern as a distinct extent pattern was the subject of some debate during the 2017 classification workshop. Localised juvenile periodontitis (LJP), included as a distinct diagnosis in the 1986 classification system and replaced by the term “localised aggressive periodontitis” in the 1999 classification, has been defined by its characteristic distribution pattern, i.e., “localised first molar/incisor presentation with interproximal attachment loss on at least two permanent teeth, one of which is a first molar, and involving no more than two teeth other than first molars and incisors.”⁴ In the 2017 classification workshop, this phenotype has been adopted as a distinct extent type ‘molar-incisor’ pattern.

Whilst the ‘/’ between ‘molar’ and ‘incisor’ does not state ‘or’ it is generally regarded as meaning ‘either/or’ and thus allows for only molar involvement, but it does not allow for incisor involvement alone. The presented case therefore fits with the 1999 definition of Localised Aggressive Periodontitis. The 2017 classification does not

specify details of the exact definition of MIP periodontitis, and therefore is assumed to map across to the original definition of Localised Aggressive Periodontitis.

It is also important to note that a molar-incisor pattern can also arise in young people who experience a chronic form of disease.⁵

Interestingly, the patient presented here would not have fitted the diagnostic criteria for LJP in the pre-1999 era, as she was 37 years old at the time of diagnosis. Hence, the present case illustrates that the extent description of molar incisor pattern in the 2017 classification system is not necessarily equivalent to what would have been a diagnosis of LJP in the 1989 classification. However, it should be noted that one cannot rule out disease onset during adolescence, as no previous patient records were available and LJP has been reported to have the potential to 'burn-out' or 'self-arrest'⁶.

References:

1. Caton JG, Armitage G, Berglundh T, et al. A new classification scheme for periodontal and peri-implant diseases and conditions - Introduction and key changes from the 1999 classification. *J Clin Periodontol* 2018;45 Suppl 20:S1-S8. doi: 10.1111/jcpe.12935 [published Online First: 2018/06/22]
2. Dietrich T, Ower P, Tank M, et al. Periodontal diagnosis in the context of the 2017 classification system of periodontal diseases and conditions – Implementation in Clinical Practice. *Brit Dent J* 2019;226(1):tbc.
3. Papananou PN, Sanz M, Buduneli N, et al. Periodontitis: Consensus report of workgroup 2 of the 2017 World Workshop on the Classification of Periodontal and Peri-Implant Diseases and Conditions. *J Clin Periodontol* 2018;45 Suppl 20:S162-S70. doi: 10.1111/jcpe.12946 [published Online First: 2018/06/22]
4. Lang NP, Bartold PM, Cullinan M, et al. Consensus report: aggressive periodontitis. *Ann Periodontol* 1999;4(1):53. doi: 10.1902/annals.1999.4.1.i [published Online First: 2000/07/15]
5. Clerehugh V, Worthington HV, Lennon M, Chandler R. Site progression of loss of attachment over 5 years in 14- to 19-year-old adolescents. *J Clin Periodontol* 1995; 22:15-21.

6. Nagy RJ, Novak KF. Aggressive Periodontitis. In: Newman MG, Takei HH, Carranza FA, eds. Carranza's Clinical Periodontology. Philadelphia: W.B. Saunders Company 2002:409-14.