



Gormley, M., Chahal, R., Gallacher, N., & Bell, C. N. A. (2019). A conventional surgical approach for removal of an ectopic tooth in the nasal cavity. *BMJ Case Reports*, 12(8). <https://doi.org/10.1136/bcr-2019-231279>

Peer reviewed version

License (if available):  
CC BY-NC

Link to published version (if available):  
[10.1136/bcr-2019-231279](https://doi.org/10.1136/bcr-2019-231279)

[Link to publication record in Explore Bristol Research](#)  
PDF-document

This is the author accepted manuscript (AAM). The final published version (version of record) is available online via BMJ Publishing Group at <https://casereports.bmj.com/content/12/8/e231279.long> . Please refer to any applicable terms of use of the publisher.

## University of Bristol - Explore Bristol Research

### General rights

This document is made available in accordance with publisher policies. Please cite only the published version using the reference above. Full terms of use are available: <http://www.bristol.ac.uk/red/research-policy/pure/user-guides/ebr-terms/>

## Case report

## A conventional surgical approach for removal of an ectopic tooth in the nasal cavity

Mark Gormley,<sup>1</sup> Ramanjot Chahal,<sup>2</sup> Nicola Gallacher,<sup>2</sup> Christopher Bell<sup>1</sup>

<sup>1</sup>Department of Oral Surgery, University of Bristol, Bristol, UK  
<sup>2</sup>Department of Oral and Maxillofacial Surgery, University of Bristol, Bristol, UK

**Correspondence to**  
 Mark Gormley,  
 mark.gormley@nhs.net

Accepted 15 July 2019

**SUMMARY**

A 40-year-old female patient presented to ears, nose and throat complaining of cacosmia and discharge from the left maxillary sinus. Her CT scan revealed an ectopic supplemental nasal tooth which could not be removed by nasoendoscopy. Therefore, a conventional intraoral surgical approach was taken. In this case, we discuss the indications for conventional surgical removal of teeth from the nasal cavity when a nasoendoscopic approach is not possible. We highlight the potential pitfalls of both conventional and nasoendoscopic approaches, including some essential considerations when treatment planning these cases.

**BACKGROUND**

Extra-oral ectopic teeth are rare, with intranasal incidence reported ranging from 0.1% to 1% in the general population.<sup>1</sup> Published case series have demonstrated that a less invasive nasoendoscopic approach can be successful, but given the variation in position of ectopic teeth within the nasal cavity and paranasal sinuses, a conventional surgical approach is sometimes required.<sup>2</sup> This patient presented with common symptoms including chronic rhinosinusitis-like symptoms and discharge, which warranted further clinical and radiographic investigation.

**CASE PRESENTATION**

A 40-year-old female patient presented to ears, nose and throat (ENT) complaining of cacosmia and discharge from the left maxillary sinus. The female had a history of epilepsy for which Tegretol was taken, with no known allergies and was a never smoker.

On presentation, the patient complained of intermittent left nostril obstruction, associated with a foul-smelling discharge ongoing for years. She also had a degree of left-sided sinofacial discomfort and a history of recurrent sinus infection. An initial diagnosis of chronic rhinosinusitis affecting the left side was given. There were no signs of facial trauma or displaced teeth and all teeth in the upper arch could be accounted for.

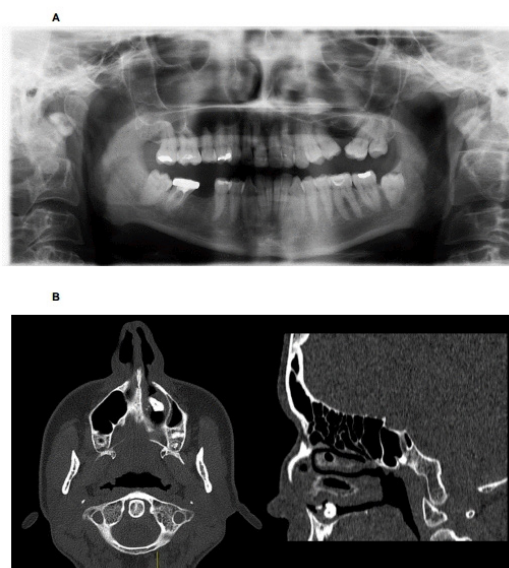
**INVESTIGATIONS**

Her orthopantomogram (figure 1A) and CT (figure 1B) scan revealed an ectopic supplemental nasal tooth. The tooth was situated within the left nasal cavity close to the lower meatus and resembled a canine, with its root abutting the junction of the hard palate and alveolar ridge. It was positioned around 4mm posterior from the anterior nasal spine. No significant pathology was seen in relation to the nasal cavity or paranasal sinuses, which were clear. ENT attempted but failed to remove the tooth using a nasoendoscopic approach, given its position. With the patient awake ENT prepared the nose with topical decongestant and local anaesthetic (2.5% phenylephrine and 5% lidocaine). A direct rigid zero-degree nasal endoscope (Karl Storz, Germany) was used (ie, rigid rhinoscopy) and grasping forceps. On the second attempt under general anaesthetic, we again attempted the procedure using the a flexible fibreoptic nasoendoscope, with visualisation on a C-MAC (Karl Storz) video monitor but had a second operator unsuccessfully try to remove the tooth using Fickling forceps.

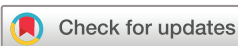**DIFFERENTIAL DIAGNOSIS**

The radiographic investigations were suggestive of a foreign body in the nose; however, the morphology and pulp chamber lead us to confirm that this was a tooth. Other potential differential diagnoses to consider in this region include the following:

- ▶ Dermoid cyst
- ▶ Exostosis
- ▶ Calcified polyp
- ▶ Rhinolith
- ▶ Benign tumours, including haemangioma, osteoma, calcified polyps, enchondroma

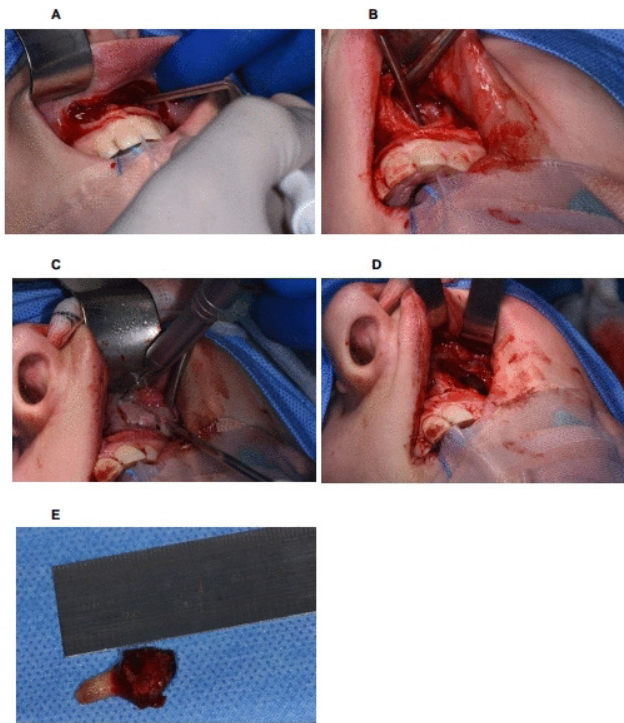


**Figure 1** (A) Orthopantomogram showing ectopic supplemental tooth positioned along the left floor of nose. (B) CT sinuses demonstrating an ectopic supplemental tooth in the left nasal cavity.



© BMJ Publishing Group Limited 2019. No commercial re-use. See rights and permissions. Published by BMJ.

**To cite:** Gormley M, Chahal R, Gallacher N, et al. *BMJ Case Rep* 2019;**12**:e231279. doi:10.1136/bcr-2019-231279



**Figure 2** Conventional surgical approach for removal of an ectopic tooth from left nasal cavity. (A) A Le Fort I incision was made in the maxillary buccal sulcus. (B) Piriform fossa identified and Howarth's periosteal elevator placed. (C) A Caldwell-Luc approach involving removal of a bony window in the upper left canine/premolar region. (D) Access through the lateral wall of the nose and the nasal mucosa elevated, along with periosteum towards the back of the hard palate. (E) Ectopic tooth removed from the nasal cavity.

- ▶ Malignant tumours, such as chondrosarcoma and osteosarcoma
- ▶ Inflammatory lesions due to syphilis, tuberculosis or fungal infection with calcification.

## TREATMENT

A conventional intraoral approach was employed. In preparation for the procedure, an oropharyngeal throat pack was placed to plan for displacement of the tooth via the nasopharynx. This was tucked behind the posterior aspect of the soft palate.

A Le Fort I incision was made in the maxillary buccal sulcus (figure 2A) and the piriform fossa identified (figure 2B). A Caldwell-Luc approach involving removal of a bony window in the upper left canine/premolar region was used to gain access to the junction of the maxillary sinus and nasal cavity (figure 2C). A hole was also made through the lateral wall of the nose and the nasal mucosa elevated, along with periosteum towards the back of the hard palate (figure 2D). Following multiple flushes using 0.9% saline, a Yankeur sucker and finger sweep of the posterior soft palate, finally displaced the tooth and it was retrieved successfully using Fickling forceps from the oropharynx. The oropharyngeal throat pack was in the ideal position to prevent dislodging the tooth towards the airway. The buccal incision was closed using Vicryl 4/0 sutures (Ethicon, Johnson & Johnson).

## OUTCOME AND FOLLOW-UP

The patient was assessed following surgery at a 4-week review and made a full recovery. No specimen was sent to histopathology as it was identifiable as a tooth (figure 2E).

## DISCUSSION

There are a number of learning points from this case. First, during the procedure, it was noted that there had been a delay of almost 12 months between the CT scan and treatment date. A delay of this length in the provision of treatment is concerning, as ectopic teeth can move position or become dislodged during this time. Tocaci and Sillifant described a case, in which, a displaced root migrated from the apex of the socket up to the ostium of the maxillary antrum via the function of the respiratory epithelium's 'mucociliary escalator' where it was then discharged.<sup>3</sup> In our case, we too questioned intraoperatively whether the tooth had moved during the time between radiographic imaging and the date of surgery, due to the continued difficulty visualising and locating the tooth.

Second, the use of an oropharyngeal throat pack, placed behind the posterior soft palate demonstrates good practice, under general anaesthetic to prevent possible airway compromise or aspiration, had the tooth possibly been displaced via the nasopharynx. Inhalation of avulsed teeth during general anaesthesia has been well reported and can result in the need for bronchoscopy with potential associated morbidity.<sup>4</sup>

The first reported ectopic nasal tooth was recorded in 1934 and since then many cases have been documented in both paediatric and adult cohorts, with a proposed incidence of between 0.1% and 1% in the general population.<sup>5 6</sup> Due to the relative rarity of ectopic teeth developing fully within the nasal cavity, there is a lack of evidence with regards to the best treatment, as most studies remain underpowered due to the small number of cases. Management often involves removal of the tooth using a transnasal endoscopically assisted approach. Rigid rhinoscopy was attempted on the awake patient in this case and a second attempt was made to remove the tooth under general anaesthetic using a flexible fibreoptic nasoendoscope with computer assistance and two operators. One randomised control trial demonstrated a clear benefit for both diagnosis and investigation using video-assisted nasoendoscopy over traditional direct flexible nasoendoscopy, but did not compare management. There were no studies comparing rigid versus flexible nasoendoscopy.<sup>7</sup>

This case demonstrates that there is still a role for a conventional surgery when nasoendoscopy fails. A conventional surgical approach is more invasive and care has to be taken to avoid the creation of an oronasal fistula which may require a complex multilayered closure. Around 25% of oronasal fistulas occur following the initial surgical repair of cleft palate or less commonly following septoplasty.<sup>8 9</sup> We found no reports of oronasal fistula as a complication following the removal of an ectopic tooth from the nasal cavity, yet it remains a potential complication. Hauer *et al* discussed that when removing midline supernumerary teeth, a modified maxillary vestibular buccal technique, with subperiosteal intranasal dissection resulted in superior visibility of the surgical field, reduced postoperative morbidity and lowered the risk of complications, in comparison to an intraoral palatal approach.<sup>10</sup> The technique employed in this case (figure 2A-E) is similar to that described by Hauer *et al*.

Conversely, Marianetti *et al* showed that patients treated with a transnasal endoscopically assisted approach required less postoperative analgesia, in contrast with conventional surgery and the average operative time was shorter. Displacement of the

tooth and subsequent airway compromise is still a potential risk with nasoendoscopy, so care must be taken when retrieving a tooth or foreign body.<sup>11</sup>

There are no absolute contraindications to nasoendoscopy, except perhaps ensuring the skill and experience of the operator. Severe nasal obstruction, craniofacial trauma with a risk of inadvertent intracranial instrumentation, severe epistaxis or difficult tooth position, as in our case, should be taken into consideration when treatment planning and may mean a conventional surgical approach is required. This case report describes in detail a conventional buccal approach which may be required when nasoendoscopic techniques fail.

### Patient's perspective

Despite having a more invasive procedure, I was glad to have the tooth in my nose removed given that symptoms, including bad smell, were affecting my quality of life every day. I was concerned regarding initial postoperative bleeding from my nose but this stopped shortly after.

### Learning points

- ▶ Use of a conventional surgical approach to remove teeth from the nasal cavity when nasoendoscopy fails.
- ▶ Use of an oropharyngeal throat pack under general anaesthetic to ensure collection of teeth displaced via the nasopharynx and to prevent airway compromise. Operators must be vigilant to prevent aspiration under general anaesthetic or during an awake nasoendoscopy.
- ▶ Ensure preoperative imaging is up-to-date, to aid accurate treatment planning and to avoid unnecessary procedures.

**Acknowledgements** Special thanks to the other operating surgeon in this case, Mr Ali Cobb.

**Contributors** Mainly authored and conceived by MG. Clinical photographs taken by MG. Editing and additions by RC, NG and editing/guidance from CB. CB was the surgeon of the described case, assisted by MG. Written patient consent was signed by MG.

**Funding** The authors have not declared a specific grant for this research from any funding agency in the public, commercial or not-for-profit sectors.

**Competing interests** None declared.

**Patient consent for publication** Obtained.

**Provenance and peer review** Not commissioned; externally peer reviewed.

### REFERENCES

- 1 Moeller ML, Bille J, Fuglsang M. Retained tooth in the nasal cavity: a rare cause of nasal congestion. *BMJ Case Rep* 2019;12:e226745.
- 2 Lee FP. Endoscopic extraction of an intranasal tooth: a review of 13 Cases. *Laryngoscope* 2001;111:1027–31.
- 3 Tocaciu S, Sillifant P. Spontaneous clearance of a dislodged root in the maxillary antrum. *Oral Surg* 2018;11:224–7.
- 4 Savage C, Zwischenberger JB. Tooth Extraction From the Distal Bronchus 12 Days After Traumatic Aspiration: Extraction of a Chronically Aspirated Tooth. *Journal of Bronchology* 2002;9:232–3.
- 5 Endicott CL. A case of a supernumerary incisor erupting into the nose. *Br Dent J* 1934;56:385.
- 6 Chen A, Huang JK, Cheng SJ, et al. Nasal teeth: report of three cases. *AJNR Am J Neuroradiol* 2002;23:671–3.
- 7 Lau JCT, Leong AC. The C-MAC® video-assisted nasoendoscopy vs traditional direct flexible nasoendoscopy: A pilot randomised controlled study. *Clin Otolaryngol* 2018;43:966–9.
- 8 Alhedaithy RA, Alsaleh SA. Oronasal fistula post-septoplasty. *Saudi Med J* 2017;38:310–3.
- 9 Sadhu P. Oronasal fistula in cleft palate surgery. *Indian J Plast Surg* 2009;42 Suppl:123.
- 10 Hauer L, Hrusak D, Jambura J, et al. Modified maxillary vestibular approach with subperiosteal intranasal dissection for surgical extractions of mesiodentes impacted in the floor of the nasal cavity. *J Craniomaxillofac Surg* 2019;47:1–5.
- 11 Marianetti TM, Torroni A, Gasparini G, et al. Transnasal endoscopic approach to the impacted maxillary canine. *J Craniofac Surg* 2014;25:1859–61.

Copyright 2019 BMJ Publishing Group. All rights reserved. For permission to reuse any of this content visit <https://www.bmj.com/company/products-services/rights-and-licensing/permissions/>  
BMJ Case Report Fellows may re-use this article for personal use and teaching without any further permission.

Become a Fellow of BMJ Case Reports today and you can:

- ▶ Submit as many cases as you like
- ▶ Enjoy fast sympathetic peer review and rapid publication of accepted articles
- ▶ Access all the published articles
- ▶ Re-use any of the published material for personal use and teaching without further permission

#### Customer Service

If you have any further queries about your subscription, please contact our customer services team on +44 (0) 207111 1105 or via email at [support@bmj.com](mailto:support@bmj.com).

Visit [casereports.bmj.com](http://casereports.bmj.com) for more articles like this and to become a Fellow