



Kaninia, S., Edey, A., Maskell, N. A., & Rice, C. M. (2021).
Natalizumab-induced pneumonitis. *Journal of Neurology*.
<https://doi.org/10.1007/s00415-021-10811-3>

Peer reviewed version

License (if available):
Unspecified

Link to published version (if available):
[10.1007/s00415-021-10811-3](https://doi.org/10.1007/s00415-021-10811-3)

[Link to publication record on the Bristol Research Portal](#)
PDF-document

This is the accepted author manuscript (AAM). The final published version (version of record) is available online via Springer at [10.1007/s00415-021-10811-3](https://doi.org/10.1007/s00415-021-10811-3). Please refer to any applicable terms of use of the publisher.

University of Bristol – Bristol Research Portal

General rights

This document is made available in accordance with publisher policies. Please cite only the published version using the reference above. Full terms of use are available:
<http://www.bristol.ac.uk/red/research-policy/pure/user-guides/brp-terms/>

Natalizumab-induced pneumonitis

Stefania Kaninia MSc MRCP^{1,2}, Anthony J. Edey FRCP³, Nick A. Maskell DM FRCP^{2,4}, and Claire M Rice PhD FRCP^{1,2}

¹ Department of Neurology, North Bristol NHS Trust, Bristol, UK

² Translational Health Sciences, Bristol Medical School, University of Bristol, Bristol, UK

³ Department of Radiology, North Bristol NHS Trust, Bristol, UK

⁴ Department of Respiratory Medicine, North Bristol NHS Trust, Bristol, UK

Dr Stefania Kaninia s.kaninia@nhs.net ORCID 0000-0002-6185-681X

Dr Anthony J. Edey anthony.edey@nbt.nhs.uk

Professor Nick A. Maskell nick.maskell@bristol.ac.uk

Dr Claire M. Rice c.m.rice@bristol.ac.uk ORCID 0000-0002-9851-4426

Correspondence: Dr Claire Rice c.m.rice@bristol.ac.uk

Clinical Neurosciences

Level 1 Learning and Research Building

Southmead Hospital, Bristol, BS10 5NB

Keywords: natalizumab

eosinophilia

pneumonitis

Declarations

Funding: No targeted funding reported. SK is supported by a fellowship from the European Committee for Treatment and Research in Multiple Sclerosis (ECTRIMS)

Conflicts of interest/Competing interests: The authors report no disclosures relevant to the manuscript

Availability of data and material: Not applicable

Code availability: Not applicable

Ethics approval: Not applicable

Consent to participate: Not applicable

Consent for publication: Written consent for publication has been obtained from the patient

Dear Sirs,

Natalizumab is an anti- α 4 integrin humanised monoclonal antibody approved for treatment of multiple sclerosis (MS) and Crohn's disease. Recognised treatment complications include infusion reactions and progressive multifocal leukoencephalopathy. We report pneumonitis associated with peripheral blood eosinophilia attributable to Natalizumab in a patient with co-existent MS and Crohn's disease.

A 39-year-old man presented with worsening dyspnoea and cough. Symptoms had been intermittent over several months and had not improved with antibiotics. There was a history of relapsing-remitting MS, Crohn's disease with short gut syndrome and a chronic perianal abscess and pancreatitis. Monthly Natalizumab infusions had been commenced 6 months prior to presentation (fig 1). Additional medications included vitamin D, folate and multivitamins. He smoked and had no history of drug allergy. On examination, there was scattered expiratory wheeze on auscultation and O₂ saturations on air were 80%, rising to >98% with 5L O₂. Inflammatory markers were elevated (C-reactive protein 115 mg/L and plasma viscosity 1.97 mPa/s). There was a raised white cell count ($21.55 \times 10^9/L$) with neutrophilia ($15.09 \times 10^9/L$) and eosinophilia ($2.87 \times 10^9/L$). Alkaline phosphatase was elevated (200 U/L) and the D-dimer was positive. Total immunoglobulin E was normal but there was a newly identified, low concentration lambda monoclonal paraprotein. Normal or negative investigations included urea and electrolytes, ferritin, anti-nuclear and anti-neutrophil cytoplasm antibodies as well as screening for severe acute respiratory syndrome coronavirus-2 (SARS-CoV-19). Vitamin D level in the peri-admission period was normal. A CT pulmonary angiogram demonstrated extensive broncho-centric and peripheral ground glass opacification with superimposed interlobular septal thickening consistent with interstitial

lung disease but no evidence of acute or chronic thromboembolic disease (fig 2). Bronchoalveolar lavage fluid was clear and contained bronchial epithelial cells and alveolar macrophages; semiquantitative assessment of the cell count demonstrated 80% macrophages, 15% neutrophils and 5% lymphocytes. No significant organisms were identified on culture including prolonged culture for mycobacteria. A diagnosis of Natalizumab-induced pneumonitis was made; the drug was withdrawn and Prednisolone 30mg was commenced. Follow up CT chest performed at 2 months, demonstrated almost complete resolution of abnormalities (fig 2) and, over a further 10 months, symptoms have not recurred despite corticosteroid wean.

Peripheral blood eosinophilia is a recognised side effect of Natalizumab therapy and has been reported to occur in 38% patients.[1] It is rarely symptomatic but, when symptoms do occur, these tend to occur in the first 12 months of treatment. There are only 3 additional reported cases of pulmonary disease in the context of eosinophilia attributed to Natalizumab,[1–3] although one case was also associated with positive PR3 ANCA serology.[2] Cases of dermatitis[4] and fasciitis[5] have also been reported.

Drug-induced interstitial lung disease is recognised following exposure to numerous medications including Alemtuzumab, another MS disease modifying therapy.[6–8] However, cases may only emerge after marketing authorisation.[9] The diagnosis is based, as in our case, on clinical, physiological and radiological findings in the context of an appropriate temporal relationship between symptoms and drug exposure and the absence of another more likely cause. Smoking and male sex have been identified as risk factors and prior exposure to immunomodulating drugs and genetic susceptibility may also be relevant.[9] The evidence basis for treatment is poor although glucocorticoids are used widely.

Identification and withdrawal of the offending agents are important to prevent irreversible complications including fibrosis.

The mechanism(s) of action underlying drug-induced eosinophilic pneumonitis remain unclear and may vary depending on the precipitant.[10, 11] Eosinophil accumulation on vascular endothelial cells is thought to occur via interleukin (IL)-4 and IL-13 promotion of vascular cell adhesion molecule (VCAM)-1 expression. IL-5 primes eosinophils and enhances their survival. Chemokine-mediated transmigration across the vessel wall is mediated via the interactions of cc chemokine ligands and their receptors, particularly cc chemokine receptor (CCR)3 and CCR5. Within lung tissue, a range of factors have been associated with eosinophil accumulation and activation including leukotriene B₄, IL-33 and periostin.[10]

This case highlights the importance of ongoing reporting of low frequency but potentially serious side effects in the post-marketing, surveillance phase of drug development. We recommend careful attention to the peripheral blood eosinophil count in those on treatment with Natalizumab, particularly when it exceeds $2 \times 10^9/L$ in the first year of treatment.[1] As with Natalizumab-induced hypersensitivity reactions, clarification of the underlying genetic susceptibility factors may permit identification of those at greater risk of symptomatic eosinophilia with the potential to improve drug safety.[12]

Acknowledgements

We are grateful to the patient for permission to publish the case report. SK is supported by a fellowship from the European Committee for Treatment and Research in Multiple Sclerosis (ECTRIMS).

Figures and legends

Figure 1 Peripheral blood eosinophil count

Baseline eosinophil counts were normal but increased after introduction of Natalizumab. Following presentation with pneumonitis at 6 months, Natalizumab was withdrawn, and eosinophilia resolved.

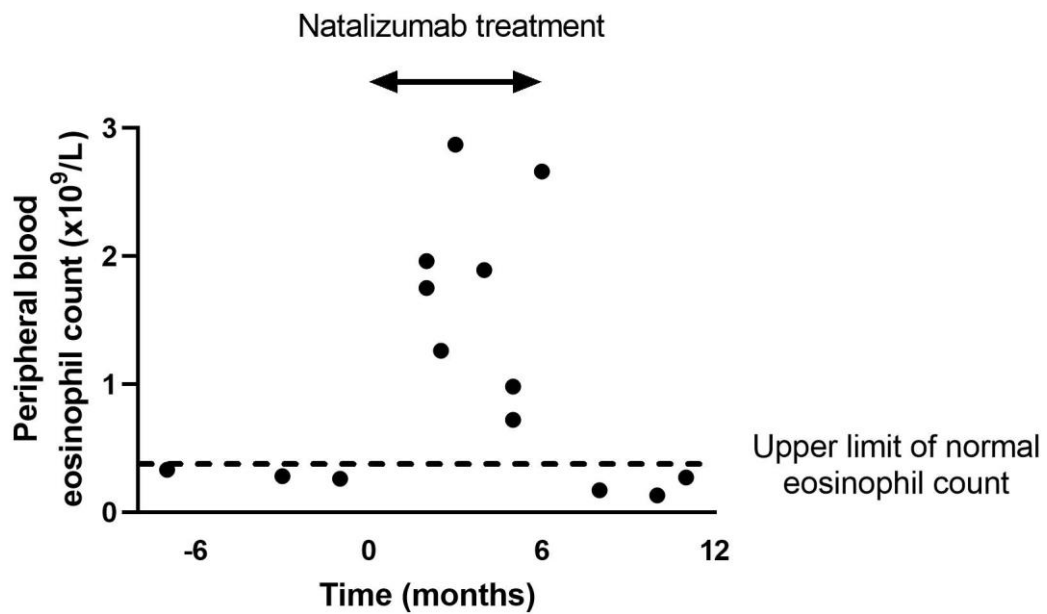
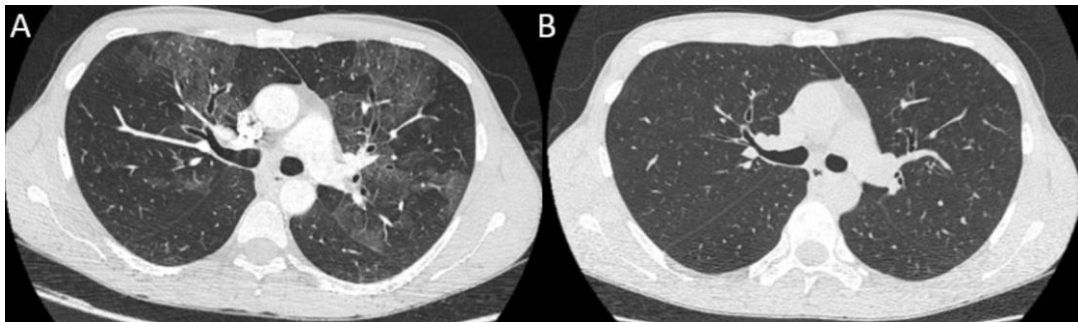


Figure 2 CT chest imaging

CT of the thorax at presentation (A) demonstrated extensive broncho-centric and peripheral ground glass opacification with superimposed interlobular septal thickening. Changes had resolved 2 months following discontinuation of Natalizumab (B).



References

1. Diem L, Hoepner R, Bagnoud M, et al (2021) Natalizumab induced blood eosinophilia: A retrospective pharmacovigilance cohort study and review of the literature. *J Neuroimmunol* 353:577505. <https://doi.org/10.1016/j.jneuroim.2021.577505>
2. Yasuda Y, Nagano T, Tachihara M, et al (2019) Eosinophilic pneumonia associated with natalizumab in a patient with multiple sclerosis: A case report and literature review. *Ther Clin Risk Manag* 15:1283–1289. <https://doi.org/10.2147/TCRM.S225832>
3. Curto E, Munteis-Olivas E, Balcells E, Domínguez-Álvarez MM (2016) Pulmonary eosinophilia associated to treatment with natalizumab. *Ann Thorac Med* 11:224–226. <https://doi.org/10.4103/1817-1737.185762>
4. Andre M, Pacheco D, Antunes J, et al (2010) Generalized skin drug eruption to natalizumab in a patient with multiple sclerosis. *Derm Online J* 16:
5. Bujold J, Boivin C, Amin M, et al (2014) Eosinophilic fasciitis occurring under treatment with natalizumab for multiple sclerosis. *J Cutan Med Surg* 18:69–71. <https://doi.org/10.2310/7750.2013.13026>
6. Willis M, Cossburn M, Ingram G, et al (2015) Hypersensitivity pneumonitis following Alemtuzumab treatment for multiple sclerosis. *J Neurol Neurosurg Psychiatry* 86:e4.31-e4. <https://doi.org/10.1136/jnnp-2015-312379.126>
7. Bianco A, Mari P-V, Larici AR, et al (2020) Alemtuzumab-induced lung injury in multiple sclerosis: Learning from adversity in three patients. *Mult Scler Relat Disord* 37:101450. <https://doi.org/10.1016/j.msard.2019.101450>
8. Whiteside D, Barth S, Datta A, Trip SA (2018) Pneumonitis secondary to alemtuzumab

in a patient with multiple sclerosis – A non-infectious cause of breathlessness. *Mult Scler Relat Disord* 22:139–140. <https://doi.org/10.1016/j.msard.2018.04.002>

9. Skeoch S, Weatherley N, Swift A, et al (2018) Drug-Induced Interstitial Lung Disease: A Systematic Review. *J Clin Med* 7:356. <https://doi.org/10.3390/jcm7100356>
10. Nakagome K, Nagata M biomolecules Possible Mechanisms of Eosinophil Accumulation in Eosinophilic Pneumonia. <https://doi.org/10.3390/biom10040638>
11. Bartal C, Sagy I, Barski L (2018) Drug-induced eosinophilic pneumonia A review of 196 case reports. <https://doi.org/10.1097/MD.00000000000009688>
12. Stüve O, Hemmer B (2014) The genetics of natalizumab hypersensitivity: One learns to itch where one can scratch. *Neurol Neuroimmunol NeuroInflammation* 1:1–4. <https://doi.org/10.1212/NXI.0000000000000052>