



Freeman, P. M., Harcourt-Brown, T. R., Jeffery, N. D., & Granger, N. (2009). Electrophysiologic evidence of polyneuropathy in a cat with signs of bilateral brachial plexus neuropathy. *Journal of the American Veterinary Medical Association*, 234(2), 240-244.
<https://doi.org/10.2460/javma.234.2.240>

Publisher's PDF, also known as Version of record

Link to published version (if available):
[10.2460/javma.234.2.240](https://doi.org/10.2460/javma.234.2.240)

[Link to publication record in Explore Bristol Research](#)
PDF-document

This article is posted on this site with the permission of the American Veterinary Medical Association, which holds the copyright for the article. For permission to distribute the article, in print or electronically, please contact the AVMA (dfagen@avma.org).

University of Bristol - Explore Bristol Research

General rights

This document is made available in accordance with publisher policies. Please cite only the published version using the reference above. Full terms of use are available:
<http://www.bristol.ac.uk/red/research-policy/pure/user-guides/ebr-terms/>

Electrophysiologic evidence of polyneuropathy in a cat with signs of bilateral brachial plexus neuropathy

Paul M. Freeman, *Vet MB*; Thomas R. Harcourt-Brown, *Vet MB*; Nick D. Jeffery, *BVSc, PhD*; Nicolas Granger, *DVM*

Case Description—A 2-year-old spayed female domestic shorthair cat was examined because of bilateral thoracic limb weakness of acute onset.

Clinical Findings—Clinical signs included muscle atrophy, paresis, depressed spinal reflexes, hyperesthesia of the thoracic limbs, and reduced jaw muscle tone. Pelvic limb reflexes were normal. Results of a neurologic examination were suggestive of multifocal lesions involving both brachial plexuses and the trigeminal nerves. Abnormal nerve conduction across the brachial plexus and delayed late potentials were found on electrodiagnostic testing, and diffuse subclinical involvement of other regions of the peripheral nervous system was confirmed on the basis of abnormal electromyographic findings for the masticatory muscles and conduction block of the peroneal nerve.

Treatment and Outcome—No specific treatments were given, and neurologic signs resolved within a month. A relapse occurred 2 months after the first episode, with clinical signs affecting both the pelvic and the thoracic limbs on this occasion. Again, the condition resolved without specific treatment, and 13 months after the initial episode, the cat reportedly was normal.

Conclusions and Clinical Relevance—Findings suggested that brachial plexus neuropathy can be a multifocal disease in cats, even if clinically apparent neurologic deficits are initially subtle or absent, and that electrodiagnostic techniques can be used to identify subclinical involvement of the peripheral nerves. (*J Am Vet Med Assoc* 2009;234:240–244)

A 2-year-old 4.2-kg (9.2-lb) neutered female domestic shorthair cat was referred to the Queen's Veterinary School Hospital of the University of Cambridge 8 days after an acute onset of thoracic limb weakness. According to the owner, the cat initially had right thoracic limb lameness, but signs progressed within 2 days to bilateral thoracic limb weakness. The cat lived indoors and had been vaccinated 7 months previously. Results of a CBC, serum biochemical panel, and urinalysis performed prior to referral were unremarkable, as were results of serologic testing for evidence of exposure to feline coronavirus, *Toxoplasma* spp, FIV, and FeLV. No obvious lesions were seen on lateral radiographic views of the vertebral column.

On initial examination at the Queen's Veterinary School Hospital, the cat had signs of bilateral thoracic limb paresis (ie, palmigrade stance and lack of extension of the elbow and shoulder joints), but pelvic limb motion appeared normal. Neurologic examination revealed marked abnormalities of postural reactions (ie, wheelbarrow, hopping, and hemiwalking) in both thoracic limbs, but pelvic limb postural reactions were normal. There was bilateral atrophy of the thoracic limb muscles, and the cat had severe signs of resentment in response to thoracic limb manipulation. Thoracic limb myotatic and flexor reflexes were markedly depressed, whereas pelvic limb reflexes were normal. Jaw tone, as-

ABBREVIATION

CMAP Compound muscle action potential

assessed by use of a standard method,¹ was found to be reduced. The cutaneous trunci reflex was absent bilaterally. No signs of pain were evident during manipulation of the neck. Signs were considered to be most likely a result of lesions involving both brachial plexuses and the motor branches of the trigeminal nerves. A focal lesion of the gray matter between spinal cord segments C6 and T2 was considered a possibility but was thought to be unlikely because of the extensive loss of muscular function in the thoracic limbs, compared with the pelvic limbs, and a lesion in this location would not explain the decreased jaw tone.

Results of a follow-up CBC and serum biochemical profile were unremarkable, other than high serum creatine kinase activity (587 U/L; reference range, 49 to 151 U/L). Ten days after the first clinical signs were noticed by the owner, the cat was anesthetized with propofol and sevoflurane, and concentric-needle electromyography of the muscles of the head, proximal and distal muscle groups of the right and left thoracic and pelvic limbs, and muscles of the cervical, thoracic, and lumbar portions of the vertebral column was performed.² Abnormal spontaneous electrical activity, including fibrillation potentials and positive sharp waves ranging from 1+ to 2+ (reference range,² 0 to 4+), was recorded in all proximal and distal muscle groups in both thoracic limbs. Fibrillation potentials were also recorded in the masseter muscles (2+) and

From the Department of Veterinary Medicine, University of Cambridge, Madingley Rd, Cambridge, CB3 0ES, England.
Supported in part by a grant from the RCVS Trust.
Address correspondence to Dr. Granger.

the left cranial tibial muscle (1+). Electroneurography of the left ulnar, radial, tibial, and peroneal nerves was performed with subdermal needles.^b For motor recordings of the ulnar, tibial, and peroneal nerves, stimulating and recording electrodes were placed as previously described for dogs.³ For stimulation of the proximal portion of the radial nerve, needles were inserted lateral to the vertebrae and medial to the scapula at the level of the C7-T1 intervertebral disc space (C8 nerve root); the transverse process of C6 and the first rib were used as anatomic landmarks. For stimulation of the distal portion of the radial nerve, needles were inserted over the distolateral aspect of the humerus, as described for dogs.³ Recording needles for stimulation of the proximal and distal portions of the radial nerve were placed in the extensor carpi radialis muscle. A single supramaximal electrical stimulus with a duration of 0.1 milliseconds was used. The amplifier was set with a low-frequency filter of 2 Hz and high-frequency filter of 10 kHz. The sensitivity was set at 5 mV. For sensory recordings of the peroneal, radial, and ulnar nerves, previously described anatomic landmarks for cats were used.⁴ Residual M-wave latency and the F ratio were calculated in the usual manner.² Results of electroneurography were compared with previously reported results.⁴⁻⁶ Because results of electroneurography of the radial nerve across the brachial plexus have not been published, the same technique was used to obtain recordings of the radial nerve in a clinically normal cat.

Compound muscle action potential amplitude was reduced in all tested nerves, except the tibial nerve (Table 1), and the ulnar nerve had extremely low CMAP amplitudes. The morphology of the CMAP elicited by stimulation of the radial nerve proximal to the brachial plexus was polyphasic with a marked increase in duration (9.7 milliseconds), compared with duration of the CMAP elicited by stimulation of the radial nerve distal to the brachial plexus (4.2 milliseconds; Figure 1). In contrast, in the clinically normal cat, amplitudes of the CMAPs elicited by stimulation of the radial nerve proximal and distal to the brachial plexus were similar to each other (approx 35 mV), and there was no evidence of temporal dispersion. There was evidence of conduction block along the peroneal nerve, as confirmed by a CMAP amplitude ratio of 0.27 for stimulation of the

proximal versus distal portion of the nerve and a percentage change in duration of 12%. Motor nerve conduction velocity was slightly reduced for the radial nerve and markedly reduced for the ulnar nerve. Compound sensory action potentials could not be recorded from the superficial branch of the radial nerve but were recorded from the ulnar and peroneal nerves, and their conduction velocities were normal (Figure 2). This finding suggested involvement of the sensory part of the radial nerve. To further distinguish distal from proximal (nerve root) disease, residual M-wave latencies were measured and F-wave studies were conducted. Residual M-wave latencies were within expected limits, whereas F-wave latencies of the ulnar and tibial nerves were high, compared with values reported for clinically normal cats.^{7c} The F ratio was also high for these 2 nerves, suggesting more proximal, rather than distal, peripheral nerve involvement.

As a whole, the electromyographic abnormalities and low CMAP amplitudes were suggestive of axonal involvement of the motor components of the brachial plexuses. The sensory branch of the radial nerve also appeared to be affected. In addition, the temporal dispersion of the CMAP after stimulation of the radial nerve root proximal to the brachial plexus specifically indicated involvement of the brachial plexus. The finding of a conduction block along the peroneal nerve with minimal electromyographic abnormalities and no clinical signs was suggestive of early demyelination. Finally, the delayed F-wave latencies and high F ratios were suggestive of proximal lesions of the peripheral nerves.

The owner declined further diagnostic testing, such as brachial plexus biopsy, peripheral nerve biopsy, and CSF analysis, at this time, and a decision was made to monitor the cat's neurologic status. Although no treatment was given, there was rapid improvement in the cat's clinical signs over the next week. One month after clinical signs had initially developed, the cat had only mild signs of thoracic limb paresis and could walk almost normally. The cat had a relapse 2 months after the first episode, with clinical signs progressing over 2 weeks before stabilizing and involving both the thoracic and pelvic limbs, confirming diffuse involvement of the peripheral nervous system. Again, there was gradual improvement over 1 month without any treatment. During a telephone

Table 1—Results of electrophysiologic testing in a cat with polyneuropathy and clinical signs of bilateral brachial plexus neuropathy.

| Variable | Tibial nerve | | Peroneal nerve | | Radial nerve | | Ulnar nerve | |
|-----------------------------------|--------------|------------------|----------------|------------------|--------------|------------------|--------------|------------------|
| | Affected cat | Reference values | Affected cat | Reference values | Affected cat | Reference values | Affected cat | Reference values |
| CAMP amplitude (mV) | | | | | | | | |
| Distal stimulation | 24.4 | 20.9 ± 3.4 | 17.0 | 30.9 ± 6.6 | 16.9 | 35.4* | 5.8 | 18.8 ± 4.7 |
| Proximal stimulation | 23.2 | 15.6 ± 4.0 | 4.6 | 29.0 ± 6.2 | 3.5 | 34.7* | 0.3 | 15.7 ± 4.8 |
| Motor conduction velocity (m/s) | 90 | 101.4 ± 12.9 | 109 | 88.3 ± 17.8 | 79 | 87* | 61 | 120.0 ± 24.4 |
| Sensory conduction velocity (m/s) | ND | 80.2 ± 7.9 | 90 | 85.3 ± 6.8 | NR | 83.6 ± 8.3 | 82 | 89.2 ± 10.3 |
| M-wave residual latency (ms) | 1.46 | 1.8 ± 0.4 | 0.42 | 1.9 ± 0.6 | 0.37 | 0.76* | 1.1 | 1.3 ± 0.3 |
| F-wave latency (ms) | 12.9 | 9.5 ± 1.0 | ND | NA | ND | NA | 11.8 | 8.4 ± 0.9 |
| F ratio | 5.45 | 1.75 ± 0.2 | ND | NA | ND | NA | 3.36 | 1.80 ± 0.21 |

Reference values are given as mean ± SD and have been published previously.^{4-6c}
*Reference values were not available; reported values represent results of electrophysiologic testing in a clinically normal cat.
NR = Not recorded. ND = Not determined. NA = Not available.

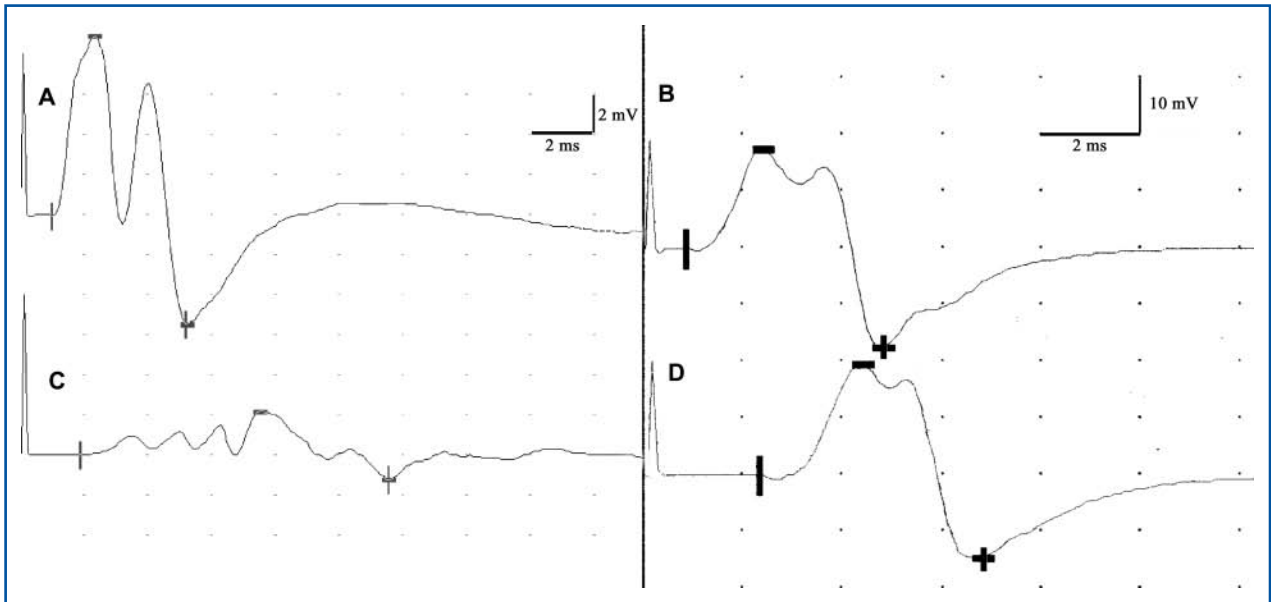


Figure 1—Compound muscle action potentials recorded from the left radial nerve in a cat with polyneuropathy (A and C) and in a clinically normal cat (B and D). Recordings were obtained after stimulation of the distal portion of the radial nerve (A and B) and after stimulation proximal to the brachial plexus (C and D). In the cat with polyneuropathy, notice the polyphasic morphology, low amplitude, and long duration of the CMAP recorded after stimulation of the nerve proximal to the brachial plexus.

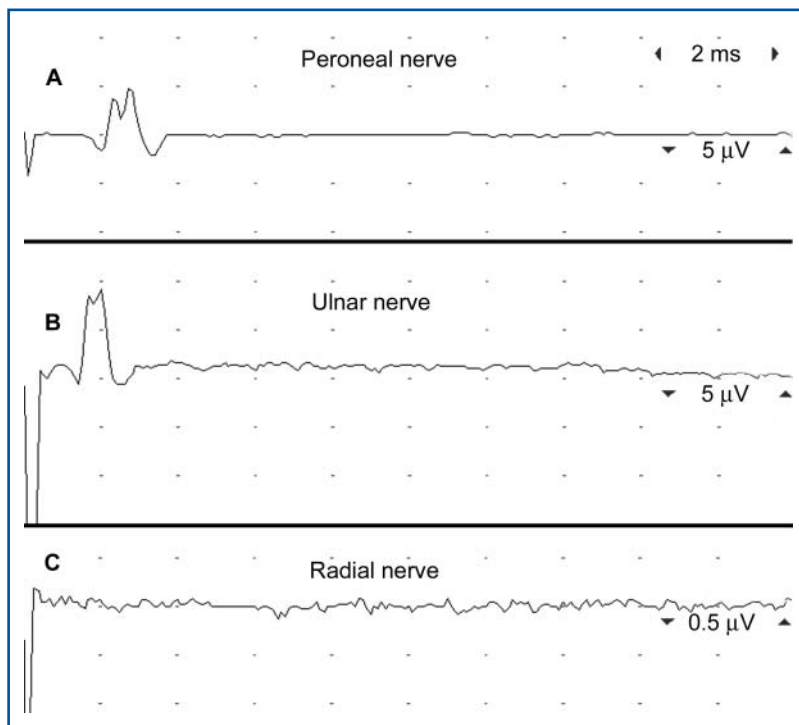


Figure 2—Sensory nerve conduction potentials recorded from the left peroneal (A), ulnar (B), and radial (C) nerves in a cat with polyneuropathy. Potentials could not be recorded from the radial nerve in the region of the distal part of the humerus, after subcutaneous stimulation of the dorsal part of the paw.

conversation 13 months after the first episode, the owner indicated that the cat appeared normal.

Discussion

Bilateral dysfunction of the brachial plexus is apparently uncommon in cats^{8,9} and dogs,^{10,11} and to our knowl-

edge, there is only a single previously published report⁸ of brachial plexus neuropathy in a cat. Importantly, although the cat described in the present report had bilateral brachial plexus lesions, we were also able to identify subclinical involvement of other peripheral motor and sensory nerves through electrodiagnostic testing.

In the cat described in the present report, signs of pain were clearly elicited by manipulation of the thoracic limbs, and results of electrodiagnostic testing were suggestive of radial nerve sensory dysfunction. In contrast, signs of pain were not described in a previous report⁸ of a cat with brachial plexus neuropathy, although a report¹¹ of a dog with brachial plexus neuropathy described intermittent periods of pain. Jaw tone in the cat described in the present report was reduced clinically, and this finding was confirmed by the abnormal electromyographic findings for the masseter muscles. Mild abnormalities were also seen during electromyography of the left cranial tibial muscle, and peroneal nerve conduction was abnormal, even though results of neurologic examination of the pelvic limbs were normal. In the previous report⁸ of a cat with brachial plexus neuropathy, results of electromyography were unremarkable and nerve conduction velocity of the tibial nerve was normal; however, the peroneal nerve was not tested. Interestingly, severe dyspnea developed in this cat⁸ and has also been identified in cats with acute idiopathic polyneuropathy.¹² Because of the additional findings in the cat described in the present report, it is

not accurate to characterize the condition as a brachial plexus neuropathy. Rather, it appeared that the cat had an acute polyneuropathy with clinical signs of bilateral brachial plexus neuropathy.

Electromyographic findings and low CMAP amplitudes in the cat described in the present report suggested that the nerve lesions in this case were predominantly a result of multifocal axonal loss. In the previous report,⁸ conduction velocity of the median nerve was markedly reduced (5.5 m/s), suggesting that lesions were the result of a demyelinating process. In the cat described in the present report, the temporal dispersion and loss of amplitude of CMAPs recorded following stimulation of the proximal portion of the radial nerve, compared with results obtained following stimulation of the distal portion of the radial nerve, suggested that there was involvement of the brachial plexus. However, it was difficult to determine whether this finding represented early demyelination, as this would imply severe involvement of large-diameter myelinated fibers and slow clinical recovery. Temporal dispersion is typically subclinical, and thoracic limb weakness in this cat was most likely attributable to disruption of axonal conduction. The prolonged duration and polyphasic morphology of the CMAPs obtained following stimulation of the proximal portion of the radial nerve can probably be explained by duration-dependent phase cancellation or focal axonal injury.^{2,13} Stimulation of the nerve roots proximal to the brachial plexus can be technically challenging, and amplitude of the recorded response depends to a great extent on the site of stimulation.² The lack of proximity of the proximal stimulating electrodes to the nerve roots could have, in itself, caused substantial temporal dispersion. However, when the same recording technique was used in a clinically normal cat, good recordings of CMAPs were obtained after supramaximal stimulation of the C8 nerve root. On the other hand, electrodiagnostic testing of the peroneal nerve is much easier and accurate in small animals, and a true conduction block without temporal dispersion was recorded when results for the proximal stimulation site (trochanteric fossa) were compared with results for the distal stimulation site (stifle joint), which was considered suggestive of demyelination. In the pelvic limbs, only the left cranial tibial muscle had electromyographic abnormalities suggestive of axonal loss. In the early stages of peripheral nerve demyelinating processes associated with mild axonal loss, clinical signs (weakness) are lacking, consistent with findings for the cat described in the present report. Interestingly, the pelvic limbs were affected when the cat had a relapse of clinical signs, suggesting that more severe (axonal) lesions of peripheral nerves in the pelvic limb occurred during the second episode. Finally, values for F-wave latency and the F ratio give definitive evidence of proximal peripheral nerve involvement.

The etiology of brachial plexus neuropathy in animals is not known. In a cat described previously,⁸ vaccination 1 month prior to the onset of clinical signs was proposed as an inciting cause, and in a dog, an allergic mechanism was suggested.¹⁰ However, the reason why the brachial plexus should have been specifically involved early in the course of the disease in these ani-

mals was not explained. In some humans with neuralgic amyotrophy, which is also known as Parsonage-Turner syndrome, acute idiopathic brachial neuritis, and serum neuritis,^{14,15} lymphocytes have increased blastogenic activity when cultured with extracts of brachial plexus nerves but not when cultured with extracts of sacral plexus nerves, suggesting an immune-mediated response directed at epitopes specific to nerves derived from the brachial plexus may play a role.¹⁶ An immune-mediated response is also suggested by the presence of complement-dependent antibodies against peripheral nerve myelin,¹⁷ histologic evidence of mononuclear inflammatory infiltrates in the brachial plexus, and electron microscopic evidence of demyelinated axons and onion-bulb formation.¹⁵

It was not possible to determine the underlying cause of the polyneuropathy in the cat described in the present report, but there probably are a limited number of peripheral nerve diseases in cats associated with spontaneous recovery, such as immune-mediated peripheral nerve diseases. Brachial plexus biopsy would have been necessary to fully characterize the condition^{9,18} but was declined by the owner. Although biopsy of a peripheral nerve, such as the peroneal nerve, would have been less technically demanding than brachial plexus biopsy, results of histologic examination of nerve biopsy specimens from dogs with brachial plexus neuropathy have been nonspecific.¹⁰ On the other hand, examination of peripheral nerve biopsy specimens may have provided information regarding demyelination, remyelination, axonal loss, and whether there was an inflammatory component to the neuropathy.

Findings in the present case revealed that brachial plexus neuropathy can be a multifocal disease in cats, even if clinically apparent neurologic deficits are initially subtle or absent. This is of importance, as it may affect how veterinarians approach such cases. Electrodiagnostic testing was crucial in confirming the multifocal involvement in this case, although nerve and muscle biopsy would have been necessary to confirm the underlying etiology and pathologic abnormalities.

-
- a. Viking Quest, Nicolet Biomedical, Madison, Wis.
 - b. Disposable subdermal needles, 0.4-mm diameter, Viasys Neurocare, Madison, Wis.
 - c. Cuddon PA. Assessment of nerve root function in neurologic disease (abstr), in *Proceedings*. 13th Am Coll Vet Intern Med Cong 1995;913.
-

References

1. Bagley RS. Chapter 3: clinical examination of the animal with suspected neurological disease. In: *Fundamentals of veterinary clinical neurology*. Oxford, England: Blackwell Publishing Ltd, 2005;57–107.
2. Kimura J. *Electrodiagnosis in diseases of nerve and muscle: principles and practice*. 3rd ed. New York: Oxford University Press, 2001.
3. Walker TL, Redding RW, Braund KG. Motor nerve conduction velocity and latency in the dog. *Am J Vet Res* 1979;40:1433–1439.
4. Redding RW, Ingram JT. Sensory nerve conduction velocity of cutaneous afferents of the radial, ulnar, peroneal, and tibial nerves of the cat: reference values. *Am J Vet Res* 1984;45:1042–1045.
5. Malik R, Ho S. Motor nerve conduction parameters in the cat. *J Small Anim Pract* 1989;30:396–400.
6. Pillai SR, Steiss JE, Wright JC. Age-related changes in peripheral nerve conduction velocities of cats. *Prog Vet Neurol* 1991;2:95–104.

7. Knecht CD, Redding RW, Wilson S. Characteristics of F and H waves of ulnar and tibial nerves in cats: reference values. *Am J Vet Res* 1985;46:977-979.
8. Bright RM, Crabtree BJ, Knecht CD. Brachial plexus neuropathy in the cat: a case report. *J Am Anim Hosp Assoc* 1978;14:612-615.
9. Garosi L, de Lahunta A, Summers B, et al. Bilateral, hypertrophic neuritis of the brachial plexus in a cat: magnetic resonance imaging and pathological findings. *J Feline Med Surg* 2006;8:63-68.
10. Cummings JF, Lorenz MD, de Lahunta A, et al. Canine brachial plexus neuritis: a syndrome resembling serum neuritis in man. *Cornell Vet* 1973;63:589-617.
11. de Lahunta A, Scott DW. A case of brachial plexus neuropathy in a dog. *J Am Anim Hosp Assoc* 1974;10:515-516.
12. Gerritsen RJ, van Nes JJ, van Niel MH, et al. Acute idiopathic polyneuropathy in nine cats. *Vet Q* 1996;18:63-65.
13. Watson BV, Nicolle MW, Brown JD. Conduction block in neuralgic amyotrophy. *Muscle Nerve* 2001;24:559-563.
14. Parsonage MJ, Turner JWA. Neuralgic amyotrophy. The shoulder-girdle syndrome. *Lancet* 1948;1:973-978.
15. Suarez GA, Giannini C, Bosch EP, et al. Immune brachial plexus neuropathy: suggestive evidence for an inflammatory-immune pathogenesis. *Neurology* 1996;46:559-561.
16. Sierra A, Prat J, Bas J, et al. Blood lymphocytes are sensitized to brachial plexus nerves in patients with neuralgic amyotrophy. *Acta Neurol Scand* 1991;83:183-186.
17. Vriesendorp FJ, Dmytrenko GS, Dietrich T, et al. Anti-peripheral nerve myelin antibodies and terminal activation products of complement in serum of patients with acute brachial plexus neuropathy. *Arch Neurol* 1993;50:1301-1303.
18. England JD. The variations of neuralgic amyotrophy. *Muscle Nerve* 1999;22:435-436.



Selected abstract for JAVMA readers from the *American Journal of Veterinary Research*

Use of tick surveys and serosurveys to evaluate pet dogs
as a sentinel species for emerging Lyme disease

Sarah A. Hamer et al

Objective—To evaluate dogs as a sentinel species for emergence of Lyme disease in a region undergoing invasion by *Ixodes scapularis*.

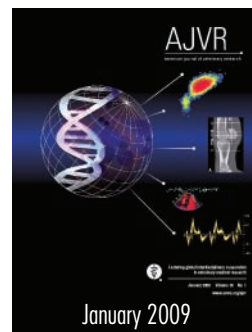
Sample Population—353 serum samples and 78 ticks obtained from dogs brought to 18 veterinary clinics located in the lower peninsula of Michigan from July 15, 2005, through August 15, 2005.

Procedures—Serum samples were evaluated for specific antibodies against *Borrelia burgdorferi* by use of 3 serologic assays. Ticks from dogs were subjected to PCR assays for detection of pathogens.

Results—Of 353 serum samples from dogs in 18 counties in 2005, only 2 (0.6%) contained western blot analysis-confirmed antibodies against *B burgdorferi*. Ten of 13 dogs with *I scapularis* were from clinics within or immediately adjacent to the known tick invasion zone. Six of 18 *I scapularis* and 12 of 60 noncompetent vector ticks were infected with *B burgdorferi*. No ticks were infected with *Anaplasma phagocytophilum*, and 3 were infected with *Babesia* spp.

Conclusions and Clinical Relevance—Serosurvey in dogs was found to be ineffective in tracking early invasion dynamics of *I scapularis* in this area. Tick chemoprophylaxis likely reduces serosurvey sensitivity in dogs. Ticks infected with *B burgdorferi* were more common and widely dispersed than seropositive dogs. In areas of low tick density, use of dogs as a source of ticks is preferable to serosurvey for surveillance of emerging Lyme disease.

Impact for Human Medicine—By retaining ticks from dogs for identification and pathogen testing, veterinarians can play an important role in early detection in areas with increasing risk of Lyme disease. (*Am J Vet Res* 2009;70:49-56)



See the midmonth issues
of JAVMA
for the expanded
table of contents
for the AJVR
or log on to
avmajournals.avma.org
for access
to all the abstracts.